Downloaded from orbit.dtu.dk on: Dec 14, 2025

DTU Library

# Vector flow imaging of the ascending aorta. Are systolic backflow and atherosclerosis related?

**Hansen, Kristoffer Lindskov; Møller-Sørensen, Hasse; Kjaergaard, Jesper; Jensen, Maiken Brit; Lund, Jens Teglgaard; Nielsen, Michael Bachmann; Jensen, Jørgen Arendt**

*Published in:*
Proceedings of 2015 IEEE International Ultrasonics Symposium

*Link to article, DOI:*
10.1109/ULTSYM.2015.0069

*Publication date:*
2015

*Document Version*
Peer reviewed version

Link back to DTU Orbit

*Citation (APA):*
Hansen, K. L., Møller-Sørensen, H., Kjaergaard, J., Jensen, M. B., Lund, J. T., Nielsen, M. B., & Jensen, J. A. (2015). Vector flow imaging of the ascending aorta. Are systolic backflow and atherosclerosis related? In *Proceedings of 2015 IEEE International Ultrasonics Symposium* IEEE. https://doi.org/10.1109/ULTSYM.2015.0069

**General rights**
Copyright and moral rights for the publications made accessible in the public portal are retained by the authors and/or other copyright owners and it is a condition of accessing publications that users recognise and abide by the legal requirements associated with these rights.

- Users may download and print one copy of any publication from the public portal for the purpose of private study or research.
- You may not further distribute the material or use it for any profit-making activity or commercial gain
- You may freely distribute the URL identifying the publication in the public portal

If you believe that this document breaches copyright please contact us providing details, and we will remove access to the work immediately and investigate your claim.

# Vector flow imaging of the ascending aorta

## Are systolic backflow and atherosclerosis related?

Kristoffer Lindskov Hansen, Hasse Møller-Sørensen, Jesper Kjaergaard, Maiken Brit Jensen, Jens Teglgaard Lund, Michael Bachmann Nielsen
University Hospital of Copenhagen
Copenhagen, Denmark

Jørgen Arendt Jensen
Center for Fast Ultrasound
DTU Elektro
Technical University of Denmark
Kgs. Lyngby, Denmark

***Abstract*—In the ascending aorta, atherosclerotic plaque formation, which is a risk factor for cerebrovascular events, most often occurs along the inner curvature. Atherosclerosis is a multifactorial disease, but the predilection site for the aortic vessel degradation is probably flow dependent. To better understand the aortic flow and especially the complex flow patterns, the ascending aorta was scanned intraoperatively in patients undergoing heart surgery using the angle-independent vector velocity ultrasound method Transverse Oscillation (TO). The primary aim of the study was to analyze systolic backflow in relation to atherosclerosis. Thirteen patients with normal aortic valves were included in to the study. TO implemented on a conventional US scanner (ProFocus 2202 UltraView, BK Medical, Herlev, Denmark) with a linear array transducer (8670, BK Medical, Herlev, Denmark) was used intraoperatively on the ascending aorta in long axis view. The presence of systolic backflow, visualized with TO, was correlated to aortic atherosclerosis, to systolic velocities obtained with transesophageal echocardiography and cardiac output obtained with pulmonary artery catheter thermodilution, to gender, age, aortic diameter, left ventricular ejection fraction (LVEF) and previous myocardial infarctions (MI). Systolic backflow in the ascending aorta was present for 38% ($n$=5) of the patients. The location of the backflow was strongly associated to the location of the plaques ($p$<0.005), and backflow was associated to high systolic velocities ($p$<0.05). The other obtained parameters were not associated to systolic backflow. It was shown that systolic backflow is a common flow feature in the ascending aorta, and that backflow is associated to atherosclerotic plaques and systolic velocities. The study indicates that vector flow imaging using TO can provide important blood flow information in the assessment of atherosclerosis.**

***Keywords*—vector velocity imaging; Transverse Oscillation; ascending aorta; systolic backflow; atherosclerosis**

## I. Introduction

Atherosclerosis is a disease of the vessel wall with accumulation of low-density lipo-proteins and migration of macrophages, resulting in plaques formation and wall thickening. Despite numerous advances in medical and surgical vascular interventions, atherosclerosis still is the leading cause of death in the Western world [1]. The development of the disease is multi-factorial, however, the prediliction sites for plaques formation are probably mainly governed by vessel geometry and blood flow [2].

The ascending aorta is a prediliction site for atherosclerosis and a major source of strokes, thus, understanding the blood flow in the ascending aorta is important for prognosis and timing for intervention [3]. Magnetic resonance (MR) and ultrasound (US) are the main modalities for imaging of aortic flow. While US is a real-time method preformed bed-side and providing 1-D velocity estimation, MR imaging is not a bed-side or a real-time modality, but is available in both 2-D and 3-D [4].

The US method Transverse Oscillation (TO) estimates the 2-D blood flow, angle-independently and in real-time [5]. Several studies have been realized with TO, examining the advantages and limitations of the method [6-10]. Furthermore, preliminary results have been published on cardiac flow using intraoperative TO [11, 12].

In this study, 13 patients with healthy aortic valves were scanned with TO intraoperatively to qualitatively describe the blood flow of the ascending aorta with special attention to systolic backflow. The systolic backflow was associated to different parameters e.g. atherosclerotic plaques, cardiac output, peak systolic velocities, previous myocardial infarction (MI) and left ventricular ejection fraction (LVEF).

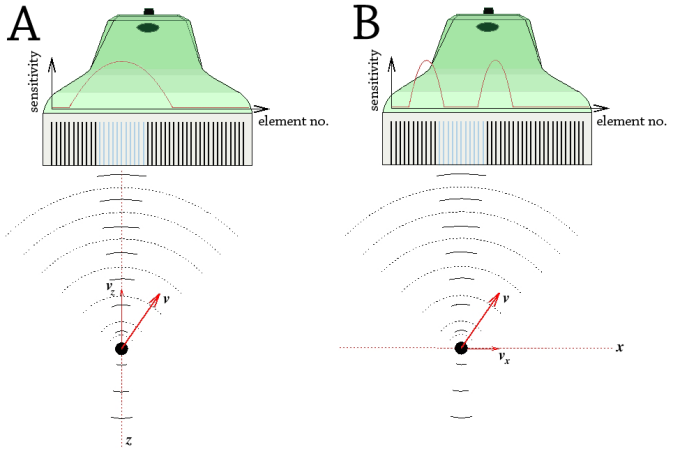


Fig. 1. A blood scatterer is moving along the red vector $v$. The axial velocity component $v_z$ is found by using a bell-shaped apodization function identical to conventional velocity estimation system (A). The transverse velocity component $v_x$ is found by using a apodization function resembling a two-point source (B). The active elements in transmit are blue, the emitted signal is shown with solid and the scattered signal with dotted lines. The apodization function is drawn as a red curve superimposed on the transducer.

The study was supported by grant number 82-2012-4 from The Danish National Advanced Technology Foundation and by BK Medical ApS.

## II. Materials and Methods

### A. Transverse Oscillation

The TO method estimates both the axial and transverse velocity component with emission of a conventional pulse for Doppler ultrasound. The motion in the axial direction is found as in conventinal Doppler ultrasound, while the motion in the transverse direction is found by using a changed apodization in receive beamforming with a special estimator (Fig. 1) [13]. Previous papers provide detailed explanations of the method [5, 6, 13].

A conventional ultrasound scanner (ProFocus 2202 UltraView, BK Medical, Herlev, Denmark) and a linear transducer (8670, BK Medical, Herlev, Denmark) under sterile settings were used to record epiaortic scan sequences in long axis view (Fig. 2).

The angle-independent vector velocities are displayed in real-time on the B-mode image as colored pixels given by a 2-D color bar defining both direction and velocity magnitude. Small arrows superimposed on to the color flow map are added to facilitate flow interpretation (Fig. 3).

The temporal resolution of TO estimation is 16 frames/s, and the maximum scan depth is approximately 5 cm due to the transducer setup available. For each scan session, the color box was adjusted to cover the lumen, and the pulse repetition frequency, depth setting, gain, and wall filtering were adjusted for vector velocity estimation. Each scan sequence corresponded to 15 s.

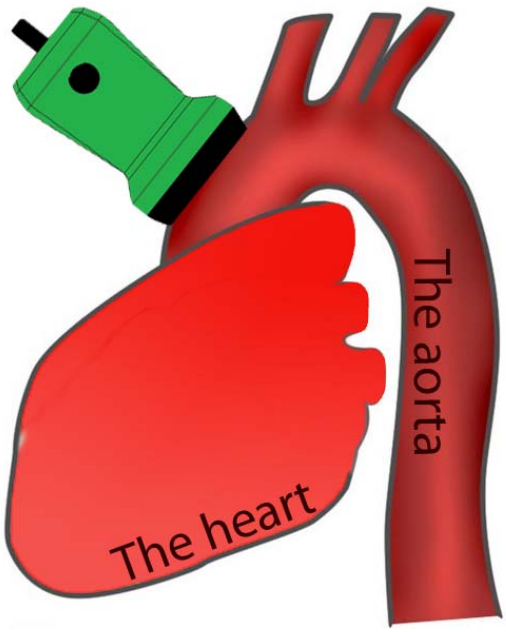


Fig. 2. Schematic drawing of the placement of the transducer directly on the ascending aorta.

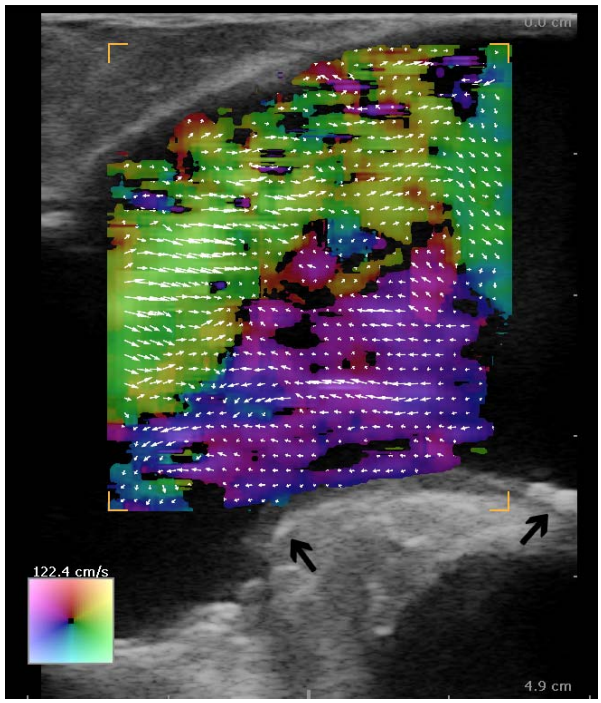


Fig. 3. Systolic backflow and atherosclerotic plaques along the inner curvature of the ascending aorta. The aortic sinus is left, and the aortic arcus is right in the image plane. The color map and vector arrows define velocity and direction of the flow. The purple colored flow corresponds to backflow, and the black arrows mark the plaques.

The presence and placement of systolic backflow were analyzed by visual inspection of the vector map, and the presence and placement of atherosclerotic plaques were noted by inspecting the B-mode sequence. The diameter of the ascending aorta was obtained by measuring the wall-to-wall distance in short axis view.

### B. Transesophageal echocardiography and pulmonary artery catheter thermodilution

Transesophageal echocardiography (TEE) was performed on a Philips iE33 scanner equipped with a Philips X7-2t transducer (Philips Healthcare, Eindhoven, The Netherlands) with the scan parameters adjusted for flow imaging. The scan sequences were obtained through the aortic valve aperture in the deep transgastric long axis view with the line of interrogation placed along the left ventricular outlet tract and the ascending aorta.

Pulmonary artery catheter thermodilution (PACTD) was performed with a 7.5F pulmonary artery catheter (Swan-Ganz Oximetry TD catheter, Baxter Edwards Critical Care, Irvine, CA, USA) and the cardiac output was determined by the HP-Philips M1012A Cardiac Output Module (Hewlett Packard, Boeblingen, Germany) as a mean of four bolus injections of 10 ml saline. TO and PACTD measurements were performed simultaneously, while TO and TEE measurements were performed within 5 min. For each patient, the medical record was consulted to obtain information on previous MI. LVEF was estimated prior to the cardiac surgery with conventional echocardiography.

### C. Statistics

Data were analyzed with descriptive statistics and comparisons were calculated with one-way ANOVA and Fisher's exact test depending on variable types. A *p*-value of less than 0.05 was considered significant. Statistical analyses were performed with IBM SPSS Statistics v. 19 (SPSS Inc., Chicago, IL, USA).

## III. Results

The study was approved by the local ethics committee (no. H-2-2012-039). Thirteen patients (12 males and 1 female, mean age 66.1 y.o., range 41-80 y.o.) without any history of valvular disease undergoing coronary bypass surgery entered the study after written informed consent.

TABLE I. DESCRIPTIVE STATISTICS

| Systolic Backflow | Number of patients | Mean age [years] | Gender (male/ female) | PACTD [l/min] | TEE [cm/s] | Diameter [mm] | Plaques (yes/no) |
|---|---|---|---|---|---|---|---|
| Present | 5 | 70.6 (8.2) | 4/1 | 4.0 (1.4) | 134.0 (39.1) | 32.6 (3.1) | 4/1 |
| Not present | 8 | 63.3 (12.1) | 8/0 | 4.9 (1.2) | 101.3 (14.3) | 31.8 (5.8) | 1/7 |
| Total | 13 | 66.1 (11.0) | 12/1 | 4.5 (1.3) | 113.8 (30.1) | 32.1 (4.8) | 5/8 |

[a.] The patients are grouped according to the presence of systolic backflow. Mean or frequency (with the standard deviation) is given for each variable.

Systolic backflow in the ascending aorta was present for 38% (*n*=5) of the patients (Table 1) and observed during the entire systole. Of the patients with backflow, three patients had backflow along the inner convexity of the aortic arch, one along the outer concavity and one along both (Table 2). Backflow was significantly associated to high systolic velocities measured by TEE ($p<0.05$) but not to PACTD ($p<0.52$) (Table 3). The location of the plaques was associated to the location of the backflow as illustrated in Fig. 1 ($p<0.005$) and shown in Table 2 and 3. All performed comparisons are given in Table 3, and as shown, no other significant associations were found.

TABLE II. SYSTOLIC BACKFLOW AND PLAQUE LOCATION

| | Atherosclerotic plaque location | | | | | |
|---|---|---|---|---|---|---|
| Systolic backflow location | | None | Concave vessel wall | Convex vessel wall | Both vessel walls | Total |
| | **None** | 7 | 1 | 0 | 0 | 8 |
| | **Concave vessel wall** | 1 | 0 | 0 | 0 | 1 |
| | **Convex vessel wall** | 0 | 0 | 3 | 0 | 3 |
| | **Both vessel walls** | 0 | 0 | 1 | 0 | 1 |
| | **Total** | 8 | 1 | 4 | 0 | 13 |

TABLE III. COMPARISONS

| | PACTD | TEE | LVEF | Plaques | Diameter | Gender | Age | Previous MI |
|---|---|---|---|---|---|---|---|---|
| Systolic Backflow | 0.52 A | **0.05** A | 0.59 A | **0.005** B | 0.79 A | 0.70 B | 0.49 A | 0.79 B |

[b.] Comparisons with *p*-values given. Significant associations are highlighted. The test used for each comparison, one-way ANOVA or Fisher's exact test, is denoted by A or B, respectively.

## IV. Discussion

Systolic backflow was seen for 38% of the patients, and the backflow was observed during the entire systole as reported previously [11, 12]. There was a strong association between the location of the backflow and location of atherosclerotic plaques (Table 2 and 3). Systolic backflow and atherosclerotic plaques were primarily found along the inner convex curvature (Table 2 and Fig. 3) as reported by others [2]. Moreover, high systolic velocities were related to the presence of backflow (Table 3).

The complex patterns in the blood flow are recognized as an essential factor for atherogenesis, and the blood flow-induced wall shear stress is thought to play a major role, as regions with low wall shear stress are predilection sites for atherosclerosis [14]. The site of plaque formation in the thoracic aorta has in previous studies been linked to retrograde flow patterns [15], and Svedlund et al. showed increased occurrence of aortic arch atheromas in patients with pronounced diastolic retrograde flow [16]. In this study, a strong association was found between the location of systolic backflow, presumably with low wall shear stress, and the location of plaques formation, and between the presence of backflow and high systolic velocities.

Bensalah et al. found systolic backflow associated to age and aortic diameter [17], however it was not found in this study, but might be a consequence of a relatively small sample size, as age seems to differ slightly between groups (Table 1).

No patient was classified with aortic stenosis, however, narrowing of the left ventricular outlet tract (LVOT) probably created the jet with high systolic velocities and adjacent systolic backflow. Thus, narrowing of LVOT may be one of the risk factors for atherogenesis in the ascending aorta, through the formation of systolic backflow as previously reported [18]. Further studies are warranted to explore this hypothesis.

The intraoperative scan approach with the Transverse Oscillation system was chosen to overcome the limited penetration depth. Hence, efforts are made for implementation of TO on phased and curved array transducers for increased penetration [19, 20]. It is evident that blood flow in the ascending aorta is highly complex and non-axisymmetrical.

Therefore, using 2-D vector flow only provides a partial visualization of the aortic blood flow, and to fully understand the aortic flow, 3-D US is warranted. 3-D vector flow using TO has been obtained, but is not yet implemented for clinical evaluation [21, 22].

With the introduction of TO in to cardiac US imaging, new insonation windows of the heart will be possible due to the angle-independency, and new information of the complex flow patterns of the cardiovascular system can be obtained.

Ischemic strokes have been linked to atheromas in the thoracic aorta [23] and the presence of retrograde flow has likewise been suspected to increase the risk of retrograde embolization to the cerebrum [16]. Therefore, evaluation of complex flow patterns in the ascending aorta is important, and the angle-independent flow estimation provided by TO is a promising visualization modality for this purpose.

Only one radiologist (KLH) evaluated the B-mode and TO sequences, which is a potential confounder. Furthermore, the relatively small study population limits this study. To confirm the presented preliminary results, a study including a larger study population with healthy aortic valve is on-going, in which, the blood flow of the ascending aorta is examined in both short and long axis view with TO.

## V. Conclusion

The complex flow in the ascending aorta among 13 patients was investigated in real-time and intraoperatively with the vector flow method TO. Systolic backflow was seen in 38% of the patients, and the backflow was present during the entire systole. The systolic backflow was strongly associated with the location of atherosclerotic plaques, moderatly associated to peak systolic velocity, but not to cardiac output, LVEF, previous MI, gender, age or aortic diameter.

Thus, the study indicates that systolic backflow and atherosclerotic plaque formation in the ascending aorta are related. The evaluation of systolic backflow may predict, which patients are prone to atherosclerotic plaque formation in the ascending aorta, and thereby, be a tool for prevention of ischemic stroke. Hence, a better understanding of the complex flow patterns in the ascending aorta may be achieved, and flow-related mechanisms in relation to aortic diseases such as atherosclerosis can be explored with the angle-independent vector velocity method TO.

## References


[1] K. Sakakura, M. Nakano, F. Otsuka *et al.*, "Pathophysiology of atherosclerosis plaque progression," *Heart Lung Circ,* vol. 22, no. 6, pp. 399-411, Jun, 2013.

[2] S. Endo, H. L. Goldsmith and T. Karino, "Flow patterns and preferred sites of atherosclerotic lesions in the human aorta - I. Aortic arch," *Biorheology,* vol. 51, no. 4, pp. 230-55, 2014.

[3] N. S. Burris and M. D. Hope, "4D flow MRI applications for aortic disease," *Magn Reson Imaging Clin N Am,* vol. 23, no. 1, pp. 15-23, Feb, 2015.

[4] K. L. Hansen, "In-vivo studies of new vector velocity and adaptive spectral estimators in medical ultrasound," *Dan Med Bull,* vol. 57, no. 5, pp. 1-23, May, 2010.

[5] J. A. Jensen and P. Munk, "A new method for estimation of velocity vectors," *IEEE Trans Ultrason Ferroelec Freq Contr,* vol. 45, pp. 837-851, 1998.

[6] J. Udesen and J. A. Jensen, "Investigation of transverse oscillation method," *IEEE Trans Ultrason Ferroelec Freq Contr,* vol. 53, pp. 959-971, 2006.

[7] K. L. Hansen, J. Udesen, N. Oddershede *et al.*, "In vivo comparison of three ultrasound vector velocity techniques to MR phase contrast angiography," *Ultrasonics,* vol. 49, no. 8, pp. 659-67, Dec, 2009.

[8] K. L. Hansen, J. Udesen, C. Thomsen *et al.*, "In vivo validation of a blood vector velocity estimator with MR angiography," *IEEE Trans Ultrason Ferroelec Freq Contr,* vol. 56, no. 1, pp. 91-100, 2009.

[9] M. M. Pedersen, M. J. Pihl, P. Haugaard *et al.*, "Comparison of real-time in vivo spectral and vector velocity estimation," *Ultrasound Med Biol,* vol. 38, no. 1, pp. 145-51, Jan, 2012.

[10] M. M. Pedersen, M. J. Pihl, P. Haugaard *et al.*, "Novel flow quantification of the carotid bulb and the common carotid artery with vector flow ultrasound," *Ultrasound Med Biol,* vol. 40, no. 11, pp. 2700-6, Nov, 2014.

[11] K. L. Hansen, H. Moller-Sorensen, M. M. Pedersen *et al.*, "First report on intraoperative vector flow imaging of the heart among patients with healthy and diseased aortic valves," *Ultrasonics,* vol. 56, pp. 243-50, 2015.

[12] K. L. Hansen, M. M. Pedersen, H. Moller-Sorensen *et al.*, "Intraoperative cardiac ultrasound examination using vector flow imaging," *Ultrason Imaging,* vol. 35, no. 4, pp. 318-32, Oct, 2013.

[13] J. A. Jensen, "A new estimator for vector velocity estimation," *IEEE Trans Ultrason Ferroelec Freq Contr,* vol. 48, pp. 886-894, 2001.

[14] E. Cecchi, C. Giglioli, S. Valente *et al.*, "Role of hemodynamic shear stress in cardiovascular disease," *Atherosclerosis,* vol. 214, no. 2, pp. 249-56, Feb, 2011.

[15] P. J. Kilner, G. Z. Yang, R. H. Mohiaddin *et al.*, "Helical and retrograde secondary flow patterns in the aortic arch studied by three-directional magnetic resonance velocity mapping," *Circulation,* vol. 88, no. 5 Pt 1, pp. 2235-47, Nov, 1993.

[16] S. Svedlund, R. Wetterholm, R. Volkmann *et al.*, "Retrograde blood flow in the aortic arch determined by transesophageal Doppler ultrasound," *Cerebrovasc Dis,* vol. 27, no. 1, pp. 22-8, 2009.

[17] M. Bensalah, E. Bollache, N. Kachenoura *et al.*, "Geometry is a major determinant of flow reversal in proximal aorta," *Am J Physiol Heart Circ Physiol,* vol. 306, no. 10, pp. 1408-16, Apr 4, 2014.

[18] K. Balachandran, P. Sucosky and A. P. Yoganathan, "Hemodynamics and mechanobiology of aortic valve inflammation and calcification," *Int J Inflam,* vol. 2011, pp. 263870, 2011.

[19] J. A. Jensen, A. H. Brandt and M. B. Nielsen, "In-vivo convex array vector flow imaging," *Proc IEEE Ultrason Symp*, pp. 333-6, 2014.

[20] M. J. Pihl, J. Marcher and J. A. Jensen, "Phased-array vector velocity estimation using transverse oscillations," *IEEE Trans Ultrason Ferroelectr Freq Control,* vol. 59, no. 12, pp. 2662-75, Dec, 2012.

[21] M. J. Pihl and J. A. Jensen, "A transverse oscillation approach for estimation of three-dimensional velocity vectors, part I: concept and simulation study," *IEEE Trans Ultrason Ferroelectr Freq Control,* vol. 61, no. 10, pp. 1599-607, Oct, 2014.

[22] M. J. Pihl, M. B. Stuart, B. G. Tomov *et al.*, "A transverse oscillation approach for estimation of three-dimensional velocity vectors, part II: Experimental validation," *IEEE Trans Ultrason Ferroelectr Freq Control,* vol. 61, no. 10, pp. 1608-18, Oct, 2014.

[23] P. Amarenco, A. Cohen, C. Tzourio *et al.*, "Atherosclerotic disease of the aortic arch and the risk of ischemic stroke," *N Engl J Med,* vol. 331, no. 22, pp. 1474-9, Dec 1, 1994.of atherosclerosis plaque progression," *Heart Lung Circ,* vol. 22, no. 6, pp. 399-411, Jun, 2013.