



## Acquired Immune Resistance Follows Complete Tumor Regression without Loss of Target Antigens or IFN gamma Signaling

**Donia, Marco; Harbst, Katja; van Buuren, Marit; Kvistborg, Pia; Lindberg, Mattias F.; Andersen, Rikke; Idorn, Manja; Ahmad, Shamaila Munir; Ellebaek, Eva; Mueller, Anja**

*Total number of authors:*  
23

*Published in:*  
Cancer Research

*Link to article, DOI:*  
[10.1158/0008-5472.CAN-16-3172](https://doi.org/10.1158/0008-5472.CAN-16-3172)

*Publication date:*  
2017

*Document Version*  
Peer reviewed version

[Link back to DTU Orbit](#)

### *Citation (APA):*

Donia, M., Harbst, K., van Buuren, M., Kvistborg, P., Lindberg, M. F., Andersen, R., Idorn, M., Ahmad, S. M., Ellebaek, E., Mueller, A., Fagone, P., Nicoletti, F., Libra, M., Lauss, M., Hadrup, S. R., Schmidt, H. N. B., Andersen, M. H., Straten, P. T., Nilsson, J. A., ... Svane, I. M. (2017). Acquired Immune Resistance Follows Complete Tumor Regression without Loss of Target Antigens or IFN gamma Signaling. *Cancer Research*, 77(17), 4562-4566. <https://doi.org/10.1158/0008-5472.CAN-16-3172>

---

### General rights

Copyright and moral rights for the publications made accessible in the public portal are retained by the authors and/or other copyright owners and it is a condition of accessing publications that users recognise and abide by the legal requirements associated with these rights.

- Users may download and print one copy of any publication from the public portal for the purpose of private study or research.
- You may not further distribute the material or use it for any profit-making activity or commercial gain
- You may freely distribute the URL identifying the publication in the public portal

If you believe that this document breaches copyright please contact us providing details, and we will remove access to the work immediately and investigate your claim.

**Title:** Acquired immune resistance follows complete tumor regression without loss of target antigens or IFN- $\gamma$  signaling

**Authors:** Marco Donia<sup>1,2</sup>, Katja Harbst<sup>3</sup>, Marit van Buuren<sup>4†</sup>, Pia Kvistborg<sup>4</sup>, Mattias F. Lindberg<sup>5</sup>, Rikke Andersen<sup>1,2</sup>, Manja Idorn<sup>1</sup>, Shamaila Munir<sup>1</sup>, Eva Ellebæk<sup>1,2</sup>, Anja Mueller<sup>6</sup>, Paolo Fagone<sup>7</sup>, Ferdinando Nicoletti<sup>7</sup>, Massimo Libra<sup>7</sup>, Martin Lauss<sup>3</sup>, Sine Reker Hadrup<sup>1</sup>, Henrik Schmidt<sup>8</sup>, Mads Hald Andersen<sup>1</sup>, Per thor Straten<sup>1</sup>, Jonas A. Nilsson<sup>4</sup>, Ton N. Schumacher<sup>5</sup>, Barbara Seliger<sup>6</sup>, Göran Jönsson<sup>3</sup>, Inge Marie Svane<sup>1,2</sup>

**Affiliations:** <sup>1</sup>Center for Cancer Immune Therapy, Department of Hematology and <sup>2</sup>Department of Oncology, Copenhagen University Hospital Herlev, Denmark. <sup>3</sup> Division of Oncology and Pathology, Department of Clinical Sciences Lund, Faculty of Medicine, Lund University, Sweden. <sup>4</sup>Division of Immunology, The Netherlands Cancer Institute, Amsterdam, The Netherlands. <sup>5</sup>Sahlgrenska Cancer Center, University of Gothenburg, Sweden <sup>6</sup>Institute for Medical Immunology, Martin Luther University Halle-Wittenberg, Germany. <sup>7</sup>Department of Bio-medical Sciences, University of Catania, Italy. <sup>8</sup>Department of Oncology, Aarhus University Hospital, Denmark. †Present address: Neon Therapeutics, Cambridge, MA, USA (MVB); Section for Immunology and Vaccinology, National Veterinary Institute, Technical University of Denmark, Copenhagen, Denmark (SRH)

**Running Title:** Acquired immune resistance following a complete response

**Keywords:** Acquired Immune resistance; Immunoediting; Melanoma; Tumor-infiltrating lymphocytes; MHC class I

**Conflict of interest:** None of the authors declares competing conflict of interests

## Additional Information

- This study was supported by grants from The Danish Cancer Society, Herlev Hospital Research Council, Aase and Einar Danielsen Foundation, Beckett Foundation (grant 36173/36228), Deutsche Krebshilfe (grant 110703 and 111091) and Fondazione Italiana per la Ricerca sul Cancro (grant 13732)
- **Correspondence addressed to:** Dr. Marco Donia, Center for Cancer Immune Therapy, Department of Hematology, Herlev Hospital. Herlev Ringvej 75, 2730 Herlev, Denmark. phone: +4538681456; Email: [marco.donia@regionh.dk](mailto:marco.donia@regionh.dk); or Prof. Inge Marie Svane, Center for Cancer Immune Therapy, Department of Hematology, Herlev Hospital. Herlev Ringvej 75, 2730 Herlev, Denmark. phone: +4538682131; Email: [inge.marie.svane@regionh.dk](mailto:inge.marie.svane@regionh.dk)
- Word Count for Main Text: 2550; Figure Count: 1; Supplementary Figures: 5; Supplementary Tables: 1; Supplementary Methods

## Abstract

Cancer immunotherapy can result in durable tumor regressions in some patients. However, patients who initially respond often experience tumor progression. Here we report mechanistic evidence of tumoral immune escape in an exemplary clinical case: a patient with metastatic melanoma who developed disease recurrence following an initial, unequivocal radiologic complete regression after T cell-based immunotherapy. Functional cytotoxic T cell responses, including responses to one mutant neo-antigen, were amplified effectively with therapy and generated durable immunological memory. However, these immune responses, including apparently effective surveillance of the tumor mutanome, did not prevent recurrence. Alterations of the MHC class I antigen processing and presentation machinery (APM) in resistant cancer cells, but not antigen loss or impaired IFN- $\gamma$  signaling, led to impaired recognition by tumor-specific CD8<sup>+</sup> T cells. Our results suggest that future immunotherapy combinations should take into account targeting cancer cells with intact and impaired MHC class I-related APM. Loss of target antigens or impaired IFN- $\gamma$  signaling does not appear to be mandatory for tumor relapse after a complete radiologic regression. Personalized studies to uncover mechanisms leading to disease recurrence within each individual patient are warranted.

## Introduction

Immunotherapy of cancer frequently results in durable clinical responses. However, a significant fraction of patients who initially respond will experience renewed tumor progression. So far, it is reported that about 30% of patients responding to checkpoint inhibitors (1,2) and about 60% of patients responding to cellular immunotherapy with tumor-infiltrating lymphocytes (TILs) (3) will experience disease progression respectively within two years and within five years. With increasing availability of immunotherapies, disease progression after initial clinical response or treatment-induced immune resistance is rapidly emerging as a major hurdle in oncology practice(4).

It is generally believed that processes leading to acquired immune resistance would practically overlap to mechanisms involved in naturally acquired resistance during primary immunoediting (5). Current knowledge on disease progression after initial response to immunotherapy is derived from comprehensive animal models, or clinical anecdotes which associate certain disease features to renewed disease progression (4). In a recent publication, Verdegaal and co-authors (6) elegantly show how immunogenic neo-antigens can be lost or downregulated during tumor progression. In this study, the authors used multiple samples from two patients with melanoma, including one patient treated with adoptive cellular therapy before collection of a progressing lesion. However, none of the samples analyzed was obtained after a true immune-mediated tumor regression, but rather during the natural progression of human melanoma or very short disease stabilization following T cell-based immunotherapy. Therefore, the relevance of these findings may be limited to the situation of prolonged immunological interactions of tumors with the adaptive immune system,

in the absence of elimination of large tumor masses. In another study, Zhao and co-authors (7) described the case of a patient with metastatic melanoma and multiple recurrent lesions, where poorly immunogenic melanoma phenotypes evolve toward T cell resistance by independent genetic events leading to MHC class I loss/deficiency. Again, this patient was treated with various forms of immunotherapy but did not appear to experience a clear immune-mediated tumor regression. In contrast, novel cancer immunotherapies frequently induce tumor regressions developing in few weeks to few months but, however, in a significant fraction of patients this initial clinical response does not last. Zaretsky and co-authors (8) described four patient cases who progressed while receiving anti-PD-1 immunotherapy, after an initial partial tumor regression. They identified defective IFN- $\gamma$  signaling and inactivation of  $\beta$ 2 microglobulin as mechanisms of acquired resistance to immunotherapy.

Here, we present mechanistic evidence of clinical tumor immune escape in an exemplary clinical case of a patient with metastatic melanoma, who developed disease recurrence following an unequivocal initial radiologic complete tumor regression to cellular immunotherapy with autologous TILs. Given the nature of this treatment, the infusion product which induced tumor regression could be studied in detail with antigen-specific assays and tests of direct tumor recognition and killing. Disease recurrence was not associated with cancer cells that lost target antigens or had impaired IFN- $\gamma$  signaling, but with cancer cells with defective MHC class I antigen processing and presentation machinery (APM).

## Materials and Methods

### Patient treatment and clinical specimens

All the procedures were approved by the Scientific Ethics Committee for the Capital Region of Denmark. Written informed consent was obtained from the patient according to the Declaration of Helsinki. HLA class I genotyping of a normal cell sample was performed by the Rigshospitalet (Copenhagen, Denmark) HLA typing service, and confirmed with whole-exome sequencing as A\*01:01, A\*03:01, B\*15:01, B\*40:01, C\*03:04 (homozygous). The patient MM909.11 was treated in the context of the clinical trial NCT00937625, and TILs were prepared accordingly as described in (9). Melanoma cell lines were established as described in (10) at the Center for Cancer Immune Therapy, Herlev Hospital, Denmark.

TILs were established according to standard methods, as described by Ellebæk E et al. (9). Briefly, TILs were initially isolated and minimally expanded (mcTILs, as in(10)) from tumor fragments in standard complete medium supplemented with IL-2 (6000 IU/ml IL-2, Proleukin, Novartis) and subsequently were massively expanded according to the Rapid Expansion Protocol (REP). PBMCs were isolated from a blood sample with gradient centrifugation, and stored according to local standard operating procedures. All melanoma cell lines, were generated by serial passage of adherent cells released from tumor fragments and cultured in RPMI 1640 (Life Technologies, Carlsbad, CA, USA) supplemented with 10% FCS (Life Technologies), as previously described (11).

The time points for collection of tumor samples (used for generation of TILs and melanoma cell lines) and PBMCs are indicated in Figure 1A. Briefly, tumor #1 was resected in February 2011, and both TIL#1 and Mel#1 were established from this sample; TIL#1 were infused in July 2011, and

this treatment resulted in a complete response according to RECIST 1.0; PBMCs were collected at serial time points; tumor #2, first identified with a PET/CT scan in August 2012 was resected in September 2012, and both TIL#2 and Mel#2 were established from this sample.

## Analysis of T-cell responses

All peptides were obtained from the NKI peptide synthesis facility (Amsterdam, The Netherlands) or Pepscan (Lelystad, The Netherlands). Combinatorial encoding with peptide(p)-MHC multimers was carried out with TIL#1 and TIL#2 to identify T cell specific for shared antigens, as described in (12). One initial screening to detect CD8<sup>+</sup> T cells in TIL#1 recognizing mutant antigens for the patient specific HLA alleles of Mel#1 was carried out as described in supplementary methods and previously used in (13). Additional focused screenings to identify whether mutant antigens privately expressed in Mel#1 were recognized was conducted by stimulating TIL#1 and TIL#2 with short peptides (8-11 mers) in overnight IFN- $\gamma$  ELISPOT assays. ELISPOT were carried out as previously described(10), using 23 additional potential private neo-epitopes of Mel#1, identified as described below (9 other private neo-epitopes were already tested in the primary screening and thus were not analyzed). Prediction of neo-epitopes is described in the supplementary file. Positive responses were confirmed with intracellular staining of TNF and IFN- $\gamma$  after stimulation of TIL#1 or TIL#2 (criteria for evaluation of positive responses were as in (11)). Responses were observed to the peptides RLSNRLLLR (TAG<sub>RLS</sub>, HLA-A3, >2% of CD8<sup>+</sup> T cells in TIL#2) and three of four tested peptides derived from the LRCH1 p.E672K mutation (CLPHHILEKK, HLA-A\*03:01, >2% of CD8<sup>+</sup> T cells in TIL#2; KLCLPHHILEK, HLA-A\*03:01, >2% of CD8<sup>+</sup> T cells in TIL#2; LEKKGLVKVGI, HLA-B\*40:01, >0.05 % of CD8<sup>+</sup> T cells in TIL#2). Since the highest responses were detected after stimulation with the mutant CLPHHILEKK peptide (data not shown), all additional experiments with recognition of the LRCH1<sub>E>K</sub> mutation were carried out with this



reagent. Responses to peptides RLSNRLLLR (TAG-derived) and CLPHHILEKK (LRCH1<sub>E>K</sub>-derived; wild type peptide CLPHHILEEK) were confirmed with >90% pure peptides in intracellular staining experiments, assessing T cells co-expressing TNF and IFN- $\gamma$ . T cell cultures with high specificity for defined antigens (>95% specific, confirmed with p-MHC multimer staining, data not shown) were obtained by sorting relevant CD8<sup>+</sup> T cells within minimally expanded TILs with tetramers conjugated with two different colours, and then performing two sequential Rapid Expansions (REP) (14) of 8-10 + 7-9 days. Standard REP media was supplemented with 2 ng/ml of IL-15 (Peprotech, Rocky Hill, NJ, USA).

In all other cases, evaluation of T-cell responses was performed as previously described (11) with tumor reactivity evaluated by assessing the amount of CD8<sup>+</sup> T cells co-expressing TNF and IFN- $\gamma$ . FACS antibodies were obtained from BD Biosciences, unless indicated otherwise. Where indicated, tumor cells were pre-treated with 100 IU/ml of recombinant human IFN- $\gamma$  (Peprotech) for 72 hours. The chromium-51 cytotoxicity assay was performed as previously described (15).

### **Gene and protein expression of tumor cells**

Analysis of mRNA and proteins (western blot) on selected APM components and putative target antigens were performed as recently described (16). Briefly, for mRNA analysis the cDNA was synthesized using the Revert Aid<sup>TM</sup> H Minus First Strand cDNA synthesis kit (Fermentas, St. Ingbert, Germany) before qPCR was performed with APM-specific primers employing the Platinum SYBR Green qPCR SuperMix-UDG (Invitrogen, Karlsruhe, Germany) for 40 cycles, 95° C, 15 s, 60° C, 30s. Relative mRNA levels for specific APM components were normalized to  $\beta$ -actin. For protein analysis by western blot, 30  $\mu$ g of protein/lane was separated on SDS-PAGE, transferred onto nitrocellulose filters and subsequently stained with APM component-specific mAbs. The

staining was detected with horseradish peroxidase (HRP) – conjugated secondary antibodies (Dako, Hamburg, Germany). The membranes were washed and protein bands were visualized with a Lumilite (Roche Diagnostics, Mannheim, Germany) and exposed to a CCD camera (Eastman Kodak, Berlin, Germany).

## Results and Discussion

The initial complete response following infusion of autologous TILs generated from an initially resected tumor metastases (TIL#1 and tumor#1) is reported in Ellebaek et al.(9). Recurrent metastatic disease (tumor#2) was diagnosed about 1 year after primary treatment (summary of the clinical history is shown in Figure 1A).

CD8<sup>+</sup> T cells recognizing one neo-antigen derived from the mutation LRCH1 p.E672K (LRCH1<sub>E>K</sub>) and the cancer-testis antigen (epitope TAG<sub>RLS</sub>) (Figure 1B, left panel) were identified in minimally cultured (mc) TIL#1. About 6% of CD8<sup>+</sup> T cells in the infusion product, derived from TIL#1, recognized the unedited melanoma (Mel#1) *in vitro*, including T cells recognizing LRCH1<sub>E>K</sub> and TAG<sub>RLS</sub> which alone corresponded to up to about 60% of the total tumor reactivity of peripheral CD8<sup>+</sup> T cells one week after infusion (Figure 1C). Therapy-induced tumor-reactive/specific CD8<sup>+</sup> T cells detected peripherally persisted beyond tumor re-growth (Figure 1C). mcTIL#2, isolated from the recurrent tumors (tumor#2, from which the cell line Mel#2 was generated), contained at least comparable frequencies of tumor-reactive/specific T cells, including three-fold higher percentages of CD8<sup>+</sup> T cells recognizing LRCH1<sub>E>K</sub> (Figure 1B and 1C). In mcTIL#2, CD8<sup>+</sup> T cells recognizing TAG<sub>RLS</sub> or LRCH1<sub>E>K</sub> did not express higher levels of co-inhibitory molecules such as PD-1, LAG-3 or TIM-3 (Supplementary Figure S1A and S1B). Thus, tumor re-growth occurred despite effective

induction of a primary complete response, continuous T cell persistence and effective infiltration of the recurrent edited tumor.

Over 80% of non-synonymous and synonymous mutations detected were identical in tumor#1, Mel#1 and Mel#2 (Supplementary Table S1), including the LRCH1<sub>E>K</sub> mutation (Figure 1D). However, while tumor#1 and Mel#1 expressed both the mutant and wild-type alleles, Mel#2 only harbored (DNA - Figure 1D) and expressed (RNA - data not shown) the mutant allele, and at a slightly higher level as compared to Mel#1 (Figure 1E). No dramatic reduced expression of the other known target antigen TAG (Supplementary Figure S2A) as well as additional putative target antigens, such as common melanocyte differentiation antigens and cancer-testis antigens with the exception of MAGE-4 (Supplementary Figure S2B), were found. However, it is important to highlight that no responses to other putative antigens were detected with the screening methods employed (see materials and methods/Analysis of T cell responses). Although Mel#1 harbored multiple putative neo-antigens that were absent in Mel#2, further focused screening efforts did neither identify CD8<sup>+</sup> T cells in TIL#1 and TIL#2 recognizing these candidate neo-antigens (data not shown). No increased expression of the immune suppressive PD-L1 was observed in Mel#2 (Supplementary Figure S2C).

Importantly, Mel#2 displayed multiple newly emerged defects in the MHC class I APM (Figure 1F for protein and Supplementary Figure S2D for mRNA in qPCR) resulting in reduced surface expression of MHC class I antigens (HLA-ABC, Supplementary Figure S2E). IFN- $\gamma$  could induce overexpression of the major APM components and other IFN- $\gamma$  inducible molecules, demonstrating that Mel#2 maintained sensitivity to IFN- $\gamma$  (Supplementary Figure S2D, S2E and S2F). Loss of heterozygosity (LOH) in chromosome 6 (HLA genes) and/or chromosome 15 ( $\beta$ 2Microglobulin-*B2M*) were previously associated with immune resistance of relapsed melanoma lesions and impaired MHC class I APM (17). Here, both Mel#1 and Mel#2 had a LOH at *HLA-A* and *HLA-B*

locus, i.e. LOH of MHC I alleles was already present before treatment (Supplementary Figure S3A and S3B). Thus, LOH in chromosome 6 happening at early stages of tumour development affected antigen presentation equally in Mel#1 and Mel#2.

Gene expression of HLA-B and HLA-C were strongly downregulated in Mel#2 (Supplementary Figure S3C), whereas only minor changes of HLA-A (Supplementary Figure S3C) and B2M (Supplementary Figure S2D and Supplementary Figure S3C) were found. Since B2M protein is an essential part of the MHC complex, the decrease in the B2M protein level observed in Mel#2 (Figure 1F) may be related to the strongly impaired expression of HLA-B and C. Chromosome 15, where *B2M* is located, shows no evidence of LOH in both Mel#1 and Mel#2 (Supplementary Figure S3D). Overall, a specific genetic or epigenetic event to explain the observed immune resistant phenotype could not be identified either at DNA (Supplementary Table S1) or RNA (Supplementary Figure S4) level.

In parallel, recognition of Mel#2 by unselected TILs (Supplementary Figure S5A and S5B for cytokine production; TIL#1 in Figure 1G for killing), CD8<sup>+</sup> PBMCs obtained at time of recurrence (Supplementary Figure S5C) or at other later time points (+15 months or + 18 months, data not shown), and TAG<sub>RLS</sub>-specific CD8<sup>+</sup> T cells (Supplementary Figure S5D) were significantly reduced, which could be partially rescued by pre-exposure of tumor cells to IFN- $\gamma$  (Supplementary Figure S5B and S5D). In contrast, recognition of Mel#2 by CD8<sup>+</sup> T cells reactive to LRCH1<sub>E>K</sub> was increased in Mel#2 and further up-regulated with IFN- $\gamma$  (Supplementary Figure S5E), in parallel to increased expression of the LRCH1<sub>E>K</sub> mutation in Mel#2 (Figure 1E).

On a different note, Mel#2 displayed different morphology with only spindle cells, in contrast to a biphasic population comprising of spindle and epithelioid cells in Mel#1, and accelerated growth compared to Mel#1 both *in vitro* (estimated doubling time ~ 35 vs 68 hours; 35% vs 10% Ki-67<sup>+</sup>) and *in vivo* (tumor size of 50 mm<sup>2</sup> reached in less than 30 vs over 70 days, Supplementary Figure

S2F). These immune-independent changes in the biology of tumor cells may have contributed to tip of the balance from tumor elimination/dormancy to radiologically evident tumor growth.

Despite obvious limitations of a single case in which a mechanistic explanation for the observed impaired MHC class I APM could not be identified, we report one instructive clinical example offering insight into the mechanisms driving disease recurrence after radiologic complete regression following cellular immunotherapy of cancer. Radiologic complete regression may leave behind microscopic cancer cell aggregates. Thus, immunological pressure may promote the outgrowth of immune resistant tumor cells with MHC class I APM deficiencies which can drive tumor recurrence even with apparently effective surveillance of the tumor mutanome and in the absence of antigen loss or defective IFN- $\gamma$  signaling. Loss of target antigens may be not essential in acquired resistance to cancer immunotherapies inducing rapid complete regression of large tumor masses with multi-target T cell responses, as tumor cells should lose several target antigens at once for an efficient immune escape.

MHC class I APM deficient tumors can be hardly targeted effectively by immunotherapies stimulating CD8<sup>+</sup> T cell responses (18). Impaired MHC class I APM may represent a universal mechanism of resistance to CD8<sup>+</sup> T cell responses targeting any tumor-antigen (19), and a dichotomy with higher MHC class I APM expression in regressing compared to progressing metastases was observed in other studies as well (20). In order to prevent or treat tumor recurrences with acquired MHC class I APM deficiency, we suggest that alternative strategies such as restoring APM via targeted-delivery of APM-inducers, or non-T cell based immune strategies should be tested. In sum, these data together with recent works by Zaretsky and co-authors (8) highlight the need of comprehensive studies of the immunological interactions within the individual patient, in order to uncover molecular mechanisms leading to acquired resistance to cancer immunotherapy on

a personalized basis.

## References

1. Ribas A, Hamid O, Daud A, Hodi FS, Wolchok JD, Kefford R, et al. Association of Pembrolizumab With Tumor Response and Survival Among Patients With Advanced Melanoma. *Jama* [Internet]. 2016;315:1600. Available from: <http://jama.jamanetwork.com/article.aspx?doi=10.1001/jama.2016.4059>
2. Schachter J, Ribas A, Long G V, Arance A, Grob J-J, Mortier L, et al. Pembrolizumab versus ipilimumab for advanced melanoma: Final overall survival analysis of KEYNOTE-006. *ASCO Annu Meet* [Internet]. 2016. page abstr 9504. Available from: <http://meetinglibrary.asco.org/content/165198-176>
3. Rosenberg S, Yang JC, Sherry RM, Kammula US, Hughes MS, Phan GQ, et al. Durable complete responses in heavily pretreated patients with metastatic melanoma using T-cell transfer immunotherapy. *Clin cancer Res* [Internet]. 2011 [cited 2012 Nov 5];17:4550–7. Available from: <http://www.pubmedcentral.nih.gov/articlerender.fcgi?artid=3131487&tool=pmcentrez&rendertype=abstract>
4. Restifo NP, Smyth MJ, Snyder A. Acquired resistance to immunotherapy and future challenges. *Nat Rev Cancer* [Internet]. Nature Publishing Group; 2016;16:121–6. Available from: <http://www.ncbi.nlm.nih.gov/pubmed/26822578>
5. Kelderman S, Schumacher TNM, Haanen JB a G. Acquired and intrinsic resistance in cancer immunotherapy. *Mol Oncol* [Internet]. Elsevier B.V; 2014 [cited 2014 Oct 21];8:1132–9.

Available from: <http://www.ncbi.nlm.nih.gov/pubmed/25106088>

6. Verdegaal EME, de Miranda NFCC, Visser M, Harryvan T, van Buuren MM, Andersen RS, et al. Neoantigen landscape dynamics during human melanoma–T cell interactions. *Nature* [Internet]. 2016; Available from: <http://www.nature.com/doifinder/10.1038/nature18945>
7. Zhao F, Sucker A, Horn S, Heeke C, Bielefeld N, Schrörs B, et al. Melanoma lesions independently acquire t-cell resistance during metastatic latency. *Cancer Res*. 2016;76:4347–58.
8. Zaretsky JM, Garcia-Diaz A, Shin DS, Escuin-Ordinas H, Hugo W, Hu-Lieskovan S, et al. Mutations Associated with Acquired Resistance to PD-1 Blockade in Melanoma. *N Engl J Med* [Internet]. 2016 [cited 2016 Aug 27]; Available from: <http://www.ncbi.nlm.nih.gov/pubmed/27433843>
9. Ellebaek E, Iversen TZ, Junker N, Donia M, Engell-Noerregaard L, Met O, et al. Adoptive cell therapy with autologous tumor infiltrating lymphocytes and low-dose Interleukin-2 in metastatic melanoma patients. *J Transl Med* [Internet]. 2012;10:169. Available from: <http://www.ncbi.nlm.nih.gov/pmc/articles/PMC3514199/pdf/1479-5876-10-169.pdf>
10. Donia M, Andersen R, Kjeldsen JW, Fagone P, Munir S, Nicoletti F, et al. Aberrant expression of MHC Class II in melanoma attracts inflammatory tumor specific CD4+ T cells which dampen CD8+ T cell antitumor reactivity. *Cancer Res* [Internet]. 2015; Available from: <http://cancerres.aacrjournals.org/cgi/doi/10.1158/0008-5472.CAN-14-2956>
11. Donia M, Hansen M, Sendrup SL, Iversen TZ, Ellebæk E, Andersen MH, et al. Methods to improve adoptive T-cell therapy for melanoma: IFN- $\gamma$  enhances anticancer responses of cell products for infusion. *J Invest Dermatol* [Internet]. 2013 [cited 2012 Nov 8];133:545–52. Available from: <http://www.ncbi.nlm.nih.gov/pubmed/23014345>

12. Andersen RS, Thruø CA, Junker N, Lyngaa R, Donia M, Ellebæk E, et al. Dissection of T-cell antigen specificity in human melanoma. *Cancer Res* [Internet]. 2012 [cited 2013 Jan 29];72:1642–50. Available from: <http://www.ncbi.nlm.nih.gov/pubmed/22311675>
13. van Rooij N, van Buuren MM, Philips D, Velds A, Toebe M, Heemskerk B, et al. Tumor Exome Analysis Reveals Neoantigen-Specific T-Cell Reactivity in an Ipilimumab-Responsive Melanoma. *J Clin Oncol* [Internet]. 2013 [cited 2013 Sep 19];16–9. Available from: <http://www.ncbi.nlm.nih.gov/pubmed/24043743>
14. Donia M, Junker N, Ellebaek E, Andersen MH, Straten PT, Svane IM. Characterization and comparison of “Standard” and “Young” tumor infiltrating lymphocytes for adoptive cell therapy at a Danish Translational Research Institution. *Scand J Immunol* [Internet]. 2011 [cited 2012 Dec 14];157–67. Available from: <http://www.ncbi.nlm.nih.gov/pubmed/21955245>
15. Junker N, Thor Straten P, Andersen MH, Svane IM. Characterization of ex vivo expanded tumor infiltrating lymphocytes from patients with malignant melanoma for clinical application. *J Skin Cancer* [Internet]. 2011 [cited 2013 Apr 21];2011:574695. Available from: [http://www.pubmedcentral.nih.gov/articlerender.fcgi?artid=3135163&tool=pmcentrez&render\\_type=abstract](http://www.pubmedcentral.nih.gov/articlerender.fcgi?artid=3135163&tool=pmcentrez&render_type=abstract)
16. Respa A, Bukur J, Ferrone S, Pawelec G, Zhao Y, Wang E, et al. Association of IFN-gamma signal transduction defects with impaired HLA class I antigen processing in melanoma cell lines. *Clin Cancer Res* [Internet]. 2011 [cited 2014 Apr 28];17:2668–78. Available from: [http://www.pubmedcentral.nih.gov/articlerender.fcgi?artid=3426200&tool=pmcentrez&render\\_type=abstract](http://www.pubmedcentral.nih.gov/articlerender.fcgi?artid=3426200&tool=pmcentrez&render_type=abstract)



17. Del Campo AB, Kyte JA, Carretero J, Zinchenko S, Méndez R, González-Aseguinolaza G, et al. Immune escape of cancer cells with beta2-microglobulin loss over the course of metastatic melanoma. *Int J cancer* [Internet]. 2014 [cited 2013 Oct 27];134:102–13. Available from: <http://www.ncbi.nlm.nih.gov/pubmed/23784959>
18. Thor Straten P, Garrido F. Targetless T cells in cancer immunotherapy. *J Immunother cancer* [Internet]. 2016 [cited 2016 Jun 29];4:23. Available from: <http://www.ncbi.nlm.nih.gov/pubmed/27096099>
19. Garrido F, Algarra I, García-lora AM. The escape of cancer from T lymphocytes : immunoselection of MHC class I loss variants harboring structural-irreversible “ hard ” lesions. 2010;1601–6.
20. Carretero R, Wang E, Rodriguez AI, Reinboth J, Ascierto ML, Engle AM, et al. Regression of melanoma metastases after immunotherapy is associated with activation of antigen presentation and interferon-mediated rejection genes. *Int J Cancer* [Internet]. 2012 [cited 2017 Apr 3];131:387–95. Available from: <http://www.ncbi.nlm.nih.gov/pubmed/21964766>

## Figure Legend

**Figure 1: T-cell immune recognition and immune resistance of melanoma in patient MM909.11.** **A**, Clinical course, tissue collection with TILs and tumor cell line generation. CR, complete response; PD, progressive disease; SD, stable disease; NED, no evidence of disease. **B**, Staining with LRCH1<sub>E>K</sub> and TAG<sub>RLS</sub> p-MHC multimers of minimally cultured TIL#1 and TIL#2 detects specific T cells in both TILs (plots are gated on live CD8<sup>+</sup> T cells). One representative experiment is shown. **C**, The frequency of CD8<sup>+</sup> T cells recognizing Mel#1 (simultaneous production of TNF and IFN-γ after co-culture), or that binds LRCH1<sub>E>K</sub> or TAG<sub>RLS</sub> fluorochrome-conjugated is shown in the graph. The percentage of tumor-antigen specific CD8<sup>+</sup> T cells increases from undetectable before infusion of TILs to detectable variable levels. Tumor-antigen specific CD8<sup>+</sup> T cells are still detectable in the blood at the time of recurrence (around 12 months after primary immunotherapy) and in mcTIL#2, indicating ability to infiltrate the recurrent tumor. **D**, Identification of LRCH1 p.E672K mutation by whole exome sequencing. In light grey, nucleotide positions correspond to the reference sequence. Mutations are displayed in dark grey. Collapsed sequencing reads are displayed. The mutation is present in a fraction of reads in Mel#1 and respective tumor sample (tumor#1), while in Mel#2 it occupies 100% of reads. The mutation is truly somatic as it is absent from the matched normal tissue. **E**, Fold change in mutant RNA expression of *LRCH1* in Mel#2 relative to Mel#1, showing increased expression of *LRCH1* in Mel#2. **F**, Multiple deficiencies in protein expression of selected components of the class I antigen processing machinery and presentation (APM) of Mel#2, compared to Mel#1. **G**, Chromium51

release assay of Mel#1 or Mel#2 after co-incubation with TIL#1 at different effector:target ratios.

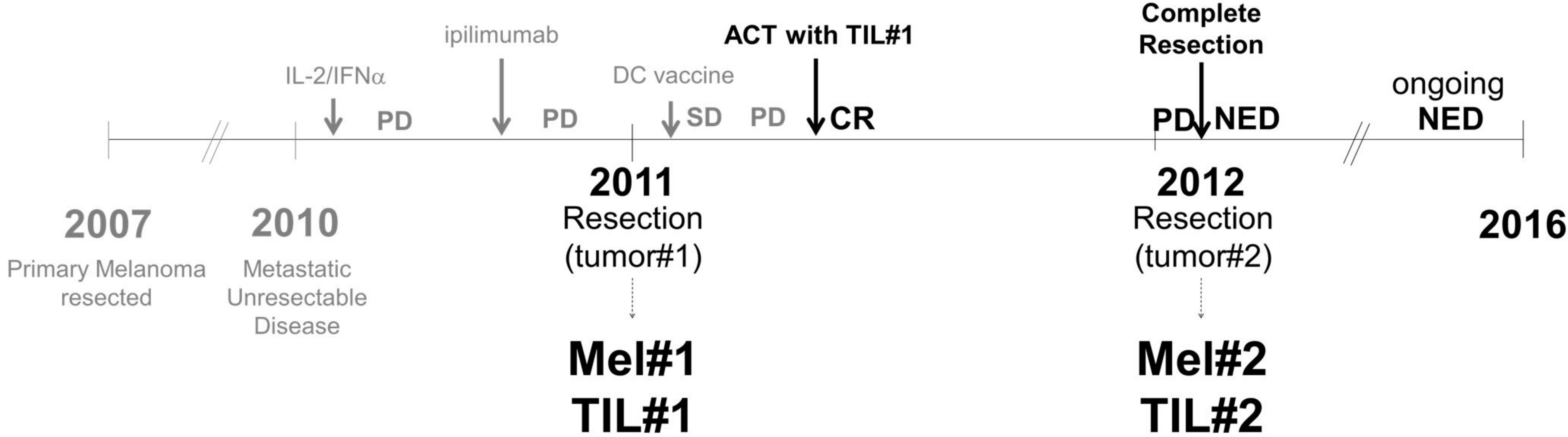
The graph shows reduced sensitivity of Mel#2.



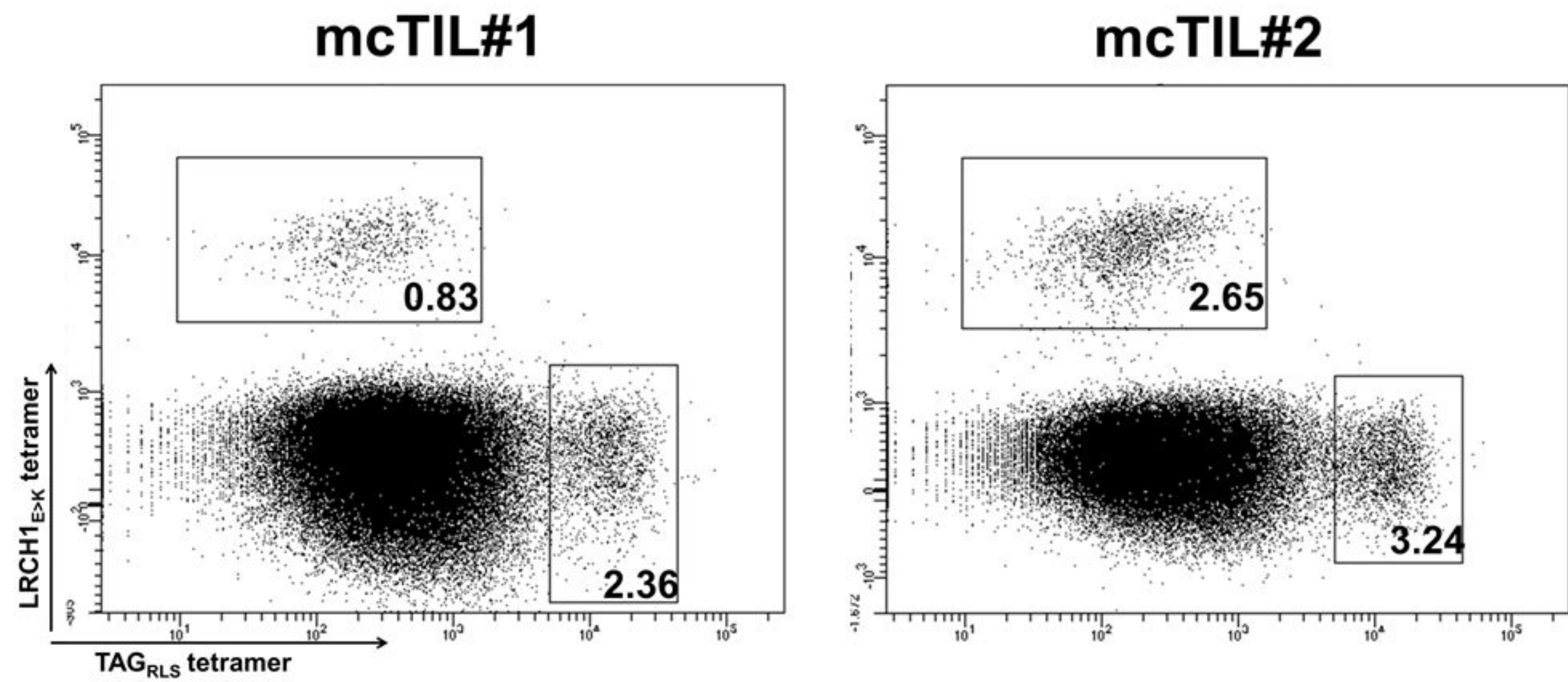
FIGURE 1

A

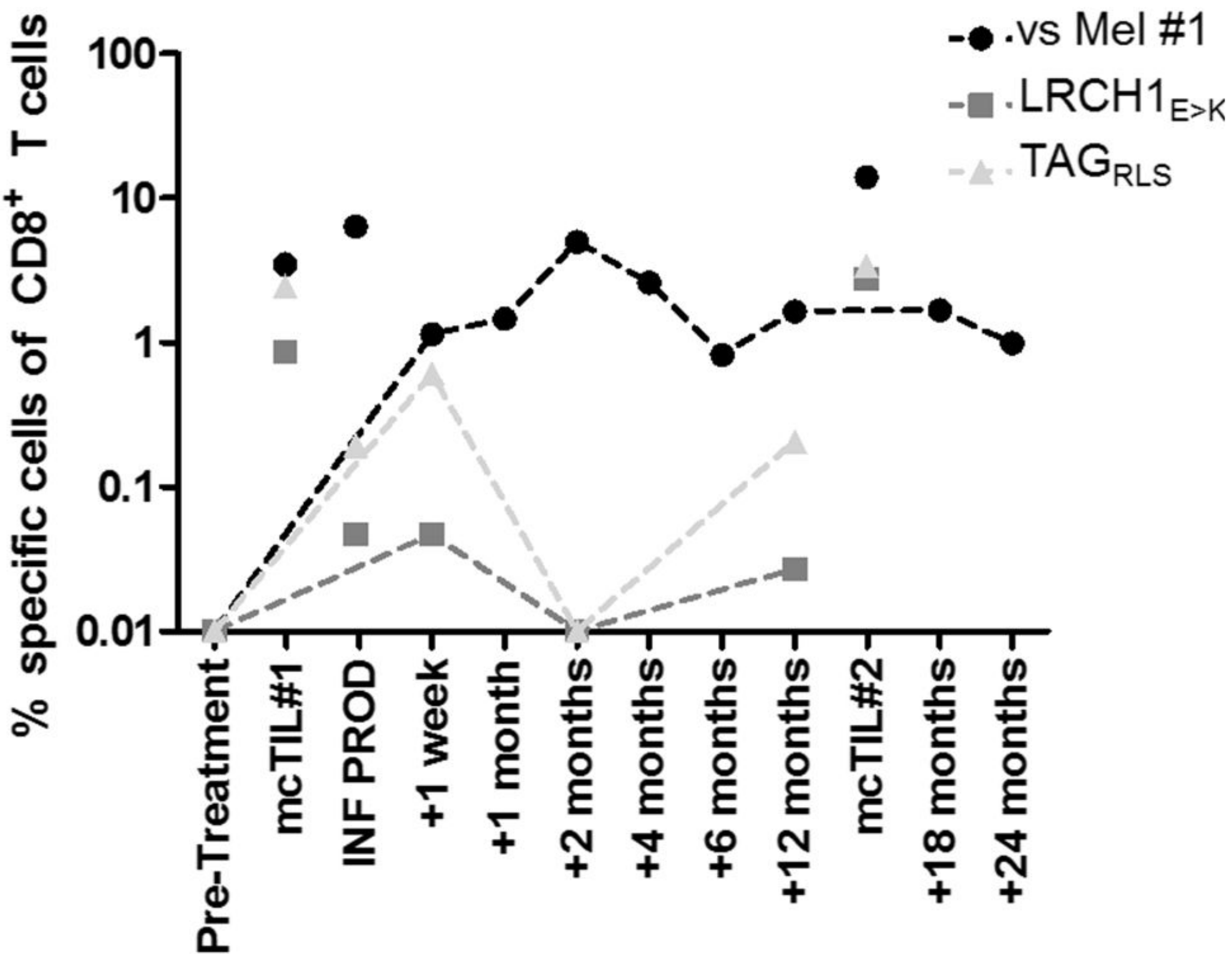
Patient MM909.11



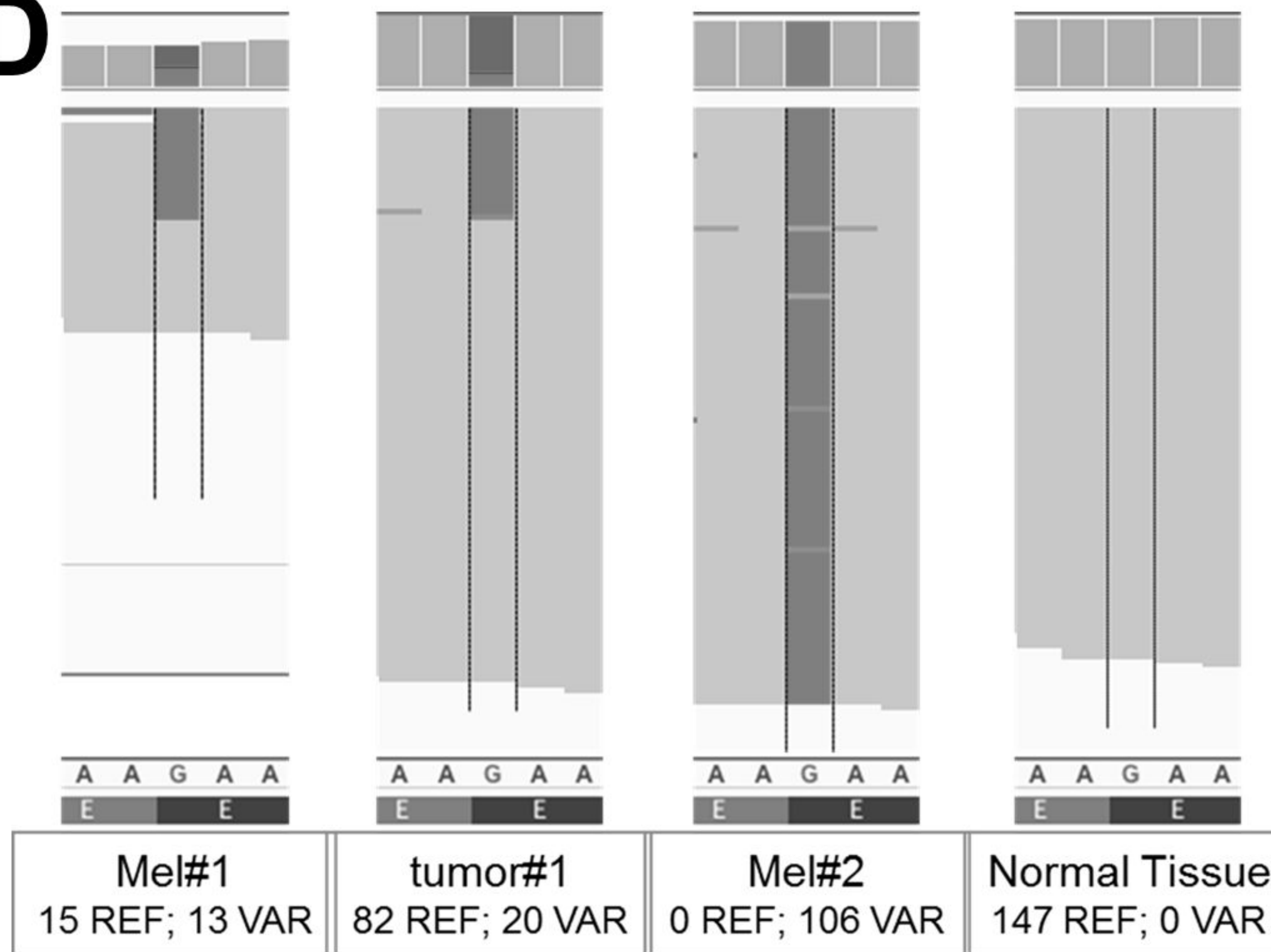
B



C

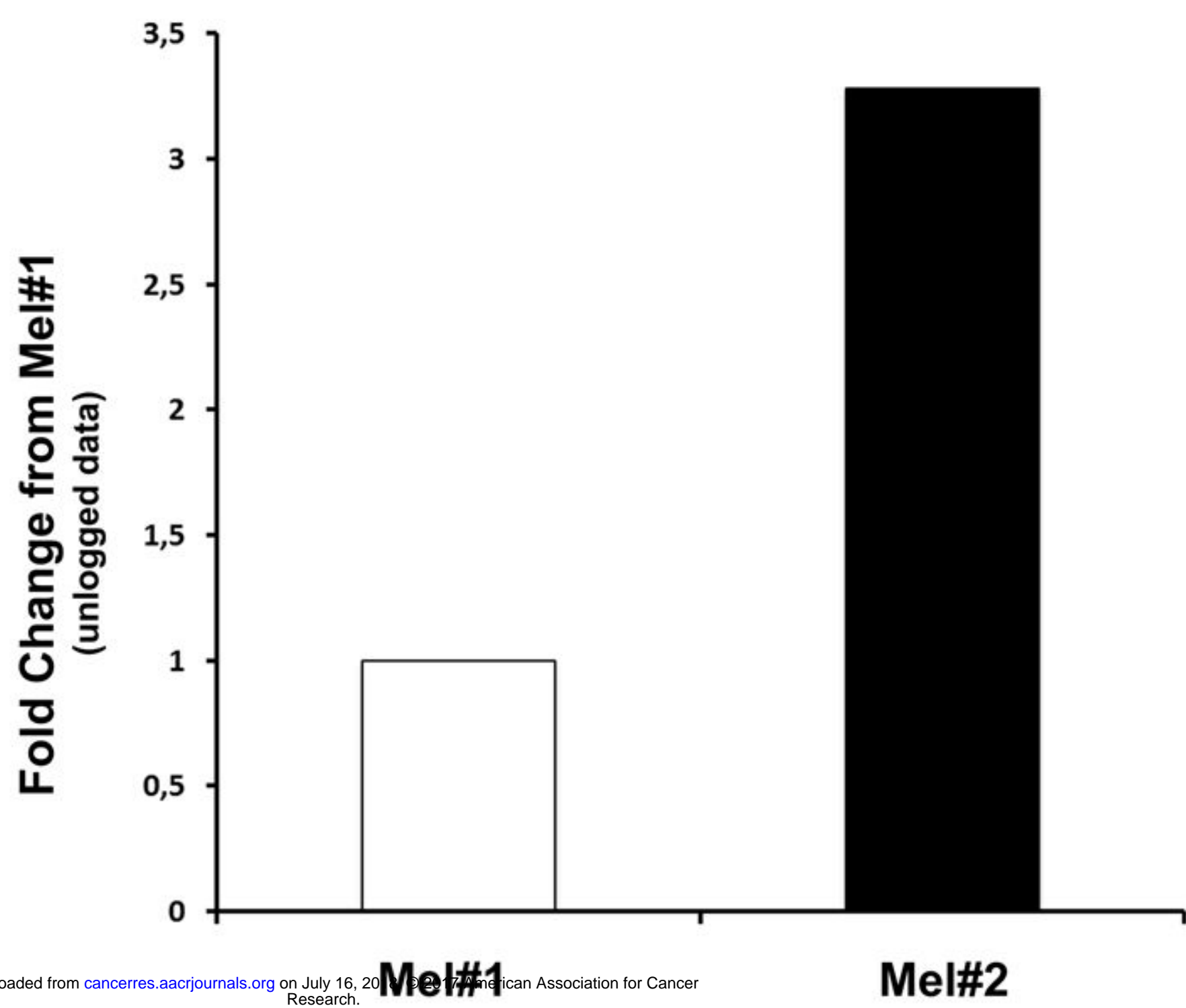


D

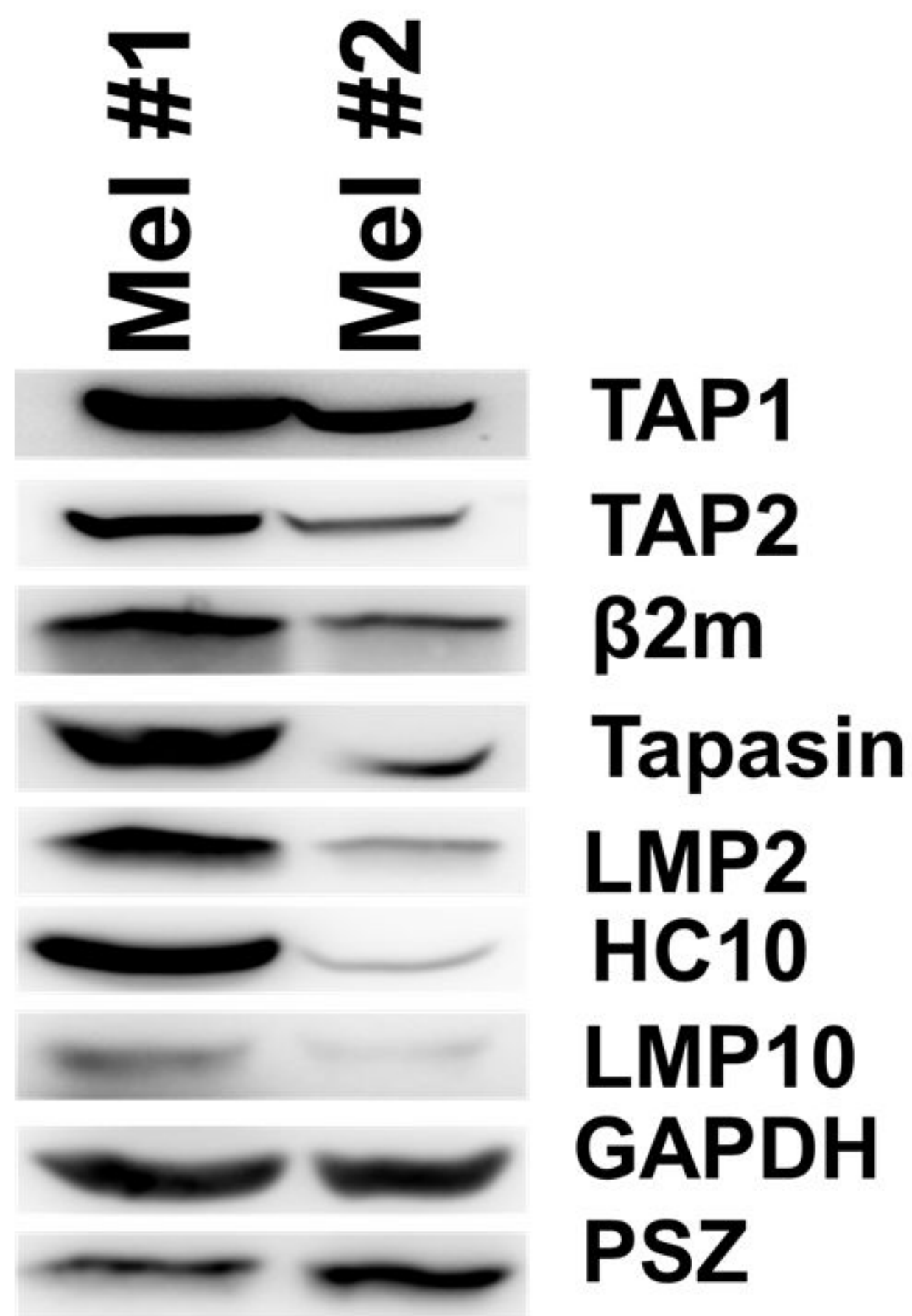


E

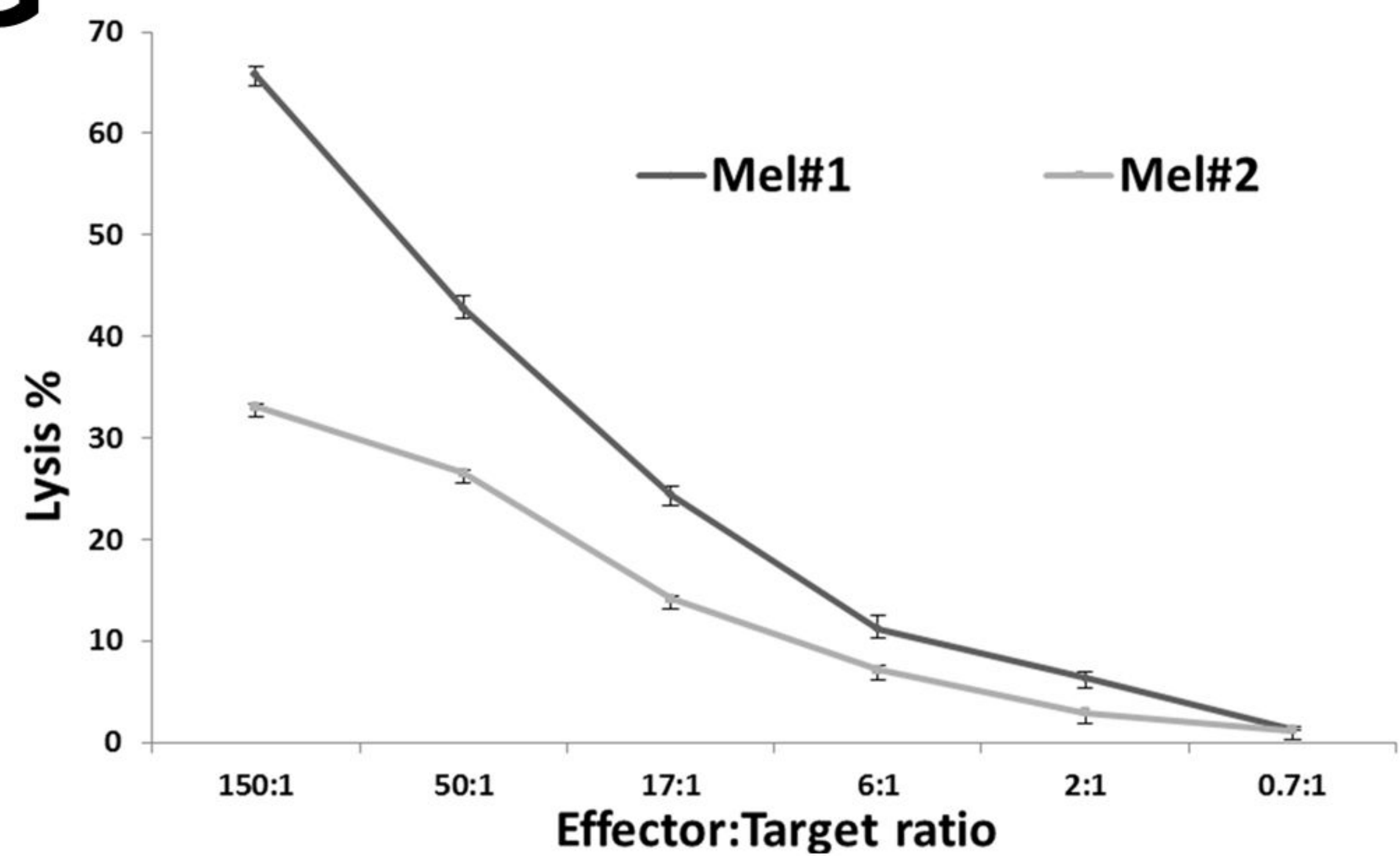
Mutant *LRCH1* expression



F



G





# Cancer Research

The Journal of Cancer Research (1916–1930) | The American Journal of Cancer (1931–1940)

## Acquired immune resistance follows complete tumor regression without loss of target antigens or IFN- $\gamma$ signaling

Marco Donia, Katja Harbst, Marit Van Buuren, et al.

*Cancer Res* Published OnlineFirst June 27, 2017.

<b>Updated version</b>	Access the most recent version of this article at: doi: <a href="https://doi.org/10.1158/0008-5472.CAN-16-3172">10.1158/0008-5472.CAN-16-3172</a>
<b>Supplementary Material</b>	Access the most recent supplemental material at: <a href="http://cancerres.aacrjournals.org/content/suppl/2017/06/27/0008-5472.CAN-16-3172.DC1">http://cancerres.aacrjournals.org/content/suppl/2017/06/27/0008-5472.CAN-16-3172.DC1</a>
<b>Author Manuscript</b>	Author manuscripts have been peer reviewed and accepted for publication but have not yet been edited.

<b>E-mail alerts</b>	<a href="#">Sign up to receive free email-alerts</a> related to this article or journal.
<b>Reprints and Subscriptions</b>	To order reprints of this article or to subscribe to the journal, contact the AACR Publications Department at <a href="mailto:pubs@aacr.org">pubs@aacr.org</a> .
<b>Permissions</b>	To request permission to re-use all or part of this article, use this link <a href="http://cancerres.aacrjournals.org/content/early/2017/06/27/0008-5472.CAN-16-3172">http://cancerres.aacrjournals.org/content/early/2017/06/27/0008-5472.CAN-16-3172</a> . Click on "Request Permissions" which will take you to the Copyright Clearance Center's (CCC) Rightslink site.