First finding of Streptococcus phocae infections in mink (Neovison vison)

Nikolaisen, Nanett Kvist; Lindegaard, Mikkel; Lyhs, Ulrike; Strube, Mikael Lenz; Hansen, Mette Sif; Struve, Tina; Chriél, Mariann; Jensen, Lars Bogø; Pedersen, Karl

Published in:
Research in Veterinary Science

Link to article, DOI:
10.1016/j.rvsc.2021.07.015

Publication date:
2021

Document Version
Publisher's PDF, also known as Version of record

Citation (APA):
Nikolaisen, N. K., Lindegaard, M., Lyhs, U., Strube, M. L., Hansen, M. S., Struve, T., Chriél, M., Jensen, L. B., & Pedersen, K. (2021). First finding of *Streptococcus phocae* infections in mink (*Neovison vison*). *Research in Veterinary Science*, *139*, 145-151. https://doi.org/10.1016/j.rvsc.2021.07.015

Research in Veterinary Science 139 (2021) 145–151

Contents lists available at ScienceDirect

Research in Veterinary Science

journal homepage: www.elsevier.com/locate/rvsc

First finding of *Streptococcus phocae* infections in mink (*Neovison vison*)

Nanett Kvist Nikolaisen [a,b,*,1], Mikkel Lindegaard [a,1], Ulrike Lyhs [a,2], Mikael Lenz Strube [a,3], Mette Sif Hansen [a,4], Tina Struve [b,5], Mariann Chriél [a], Lars Bogø Jensen [c], Karl Pedersen [a,6]

[a] National Veterinary Institute, Technical University of Denmark, Kongens Lyngby, Denmark
[b] Department of Health and Diagnostics, Kopenhagen Fur a.m.b.a., Glostrup, Denmark
[c] DTU National Food Institute, Research group for Microbiology and Hygiene, Technical University of Denmark, Kongens Lyngby, Denmark

ARTICLE INFO

Keywords:
S. phocae
Mink
Harbor seal
Phoca vitulina
Whole genome sequencing
Pathology

ABSTRACT

Streptococcus phocae infection has been described in salmon, sea otters, and several families of pinnipeds. The pathology of the infected animals has mainly been located in the respiratory tract and reproductive system, and with indications of septicemia. In this study, we report the finding of *S. phocae* in diagnostic material from three unrelated cases of farmed mink. Since *S. phocae* initially has been described in pinnipeds, two isolates from wild harbor seals were included. All isolates originated from Denmark. To our knowledge, this is the first report of *S. phocae* infection in mink.

The animals (three mink, two seals) were necropsied, and samples were collected for bacteriology, virology, and histopathology. Additionally, the *S. phocae* isolates were whole genome sequenced and compared to sequences of previously reported isolates from other host species.

S. phocae was isolated from the lungs of one mink and one seal with bacteremia, and from one seal with pneumonia. The two remaining mink had dermal infections on the paws and *S. phocae* was isolated from the lesions. The analysis of the sequence data showed that the three mink isolates and one seal isolate were closely related.

Further investigation is needed to conclude whether *S. phocae* is establishing as commensal in farmed mink and to uncover the infection related pathology in mink. *Streptococcus phocae* has been described as an emerging pathogen in other species, therefore future awareness and surveillance of this pathogen is crucial.

1. Introduction

Streptococcus phocae is a beta-hemolytic species, belonging to Lancefield's groups C, F or G or untypeable isolates. The species was first isolated and described in Norway from lung specimens from harbor seals (*Phoca vitulina*) suffering from pneumonia (Skaar et al., 1994).

This opportunistic pathogenic bacterium has been identified among several species of pinnipeds like Cape fur seals (*Arctocephalus pusillus pusillus*), Caspian seals (*Phoca caspica),* spotted seal (*Pocha largha),* harbor seal (*Phoca vitulina*), sea lions (*Zalophus californianus*) (Henton et al., 1999; Hueffer et al., 2011; Johnson et al., 2006; Kuiken et al., 2006; Raverty et al., 2004; Taurisano et al., 2018; Vossen et al., 2004), and sea otters (*Enhydra lutris nereis*) (Imai et al., 2009). In 2005, it was identified in salmon (*Salmo salar*) (Gibello et al., 2005) and later described as an emerging pathogen in the salmon industry in Chile where it has caused high mortality in affected farms and considerable economical losses (Romalde et al., 2008). These salmon pathogenic strains have been referred to a separate subspecies, *S. phocae* subsp. *salmonis* with the type strain C-4^T (Avendaño-Herrera et al., 2014). Consequently, the seal pathogenic strains were referred to *S. phocae* subsp. *phocae* with the strain defined in the original species description by Skaar et al. (1994), ATCC 51973 as the type culture. The findings of

* Corresponding author at: National Veterinary Institute, Technical University of Denmark, Kongens Lyngby, Denmark.
E-mail address: nannik@food.dtu.dk (N.K. Nikolaisen).
[1] Present address: DTU National food institute, Research group for Microbiology and Hygiene, Technical University of Denmark, Kongens Lyngby, Denmark.
[2] Present address: Department of Equine and Small Animal Medicine, Faculty of Veterinary Medicine, University of Helsinki, Finland.
[3] Present address: DTU Bioenginering, Department of Biotechnology and Biomedicine, Technical University of Denmark, Kongens Lyngby, Denmark.
[4] Present address: Section of Pathology, Department of Veterinary and Animal Sciences, University of Copenhagen, Denmark.
[5] Present address: Novozymes A/S, Microbial Safety, Bagsværd, Denmark
[6] Present address: National Veterinary Institute, Uppsala, Sweden.

https://doi.org/10.1016/j.rvsc.2021.07.015
Received 16 September 2020; Received in revised form 24 June 2021; Accepted 13 July 2021
Available online 16 July 2021

S. phocae are geographically widespread; from the first finding in Norway (Skaar et al., 1994), in Namibia (Henton et al., 1999), to the Caspian sea (Kuiken et al., 2006), and dispersed along the coasts of the South and North American continents (Hueffer et al., 2011; Imai et al., 2009; Johnson et al., 2006; Raverty et al., 2004; Romalde et al., 2008; Taurisano et al., 2018).

In seals, clinical signs of respiratory disease have been described along with macroscopic pathological findings such as pneumonia (consolidation of lung tissue, purulent exudate, interlobular edema, emphysema) (Henton et al., 1999; Skaar et al., 1994; Taurisano et al., 2018). *Streptococcus phocae* has been isolated from lungs, but also from kidneys, spleen and liver, which indicates septicemia (Skaar et al., 1994; Taurisano et al., 2018). In addition, the pathogen has been isolated from pyometra in a seal (Hueffer et al., 2011) and also in genital infections in sea lions (Johnson et al., 2006). In seals, *S. phocae* infections have been associated as secondary infections to distemper (Henton et al., 1999; Kuiken et al., 2006; Raverty et al., 2004; Skaar et al., 1994; Vossen et al., 2004).

Here we report the findings of *S. phocae* in three unrelated cases of farmed mink (*Neovison vison)* from Denmark. The mink were submitted to the National Veterinary Institute at the Technical University of Denmark for necropsy due to skin lesions or increased mortality on the farms. To the authors' knowledge, there are no other reports of *S. phocae* in mink or other farmed fur animals. For comparison, two isolates from two harbor seals submitted for necropsy at the National Veterinary Institute as part of passive disease surveillance in Danish wildlife are included.

2. Materials and methods

2.1. Animals

Three unrelated cases of diseased mink were submitted, two in August 2017 and one in April 2018, to the National Veterinary Institute, Technical University of Denmark for diagnostic examination. The animals were necropsied and subjected to standard pathological and microbiological examination as previously described by Nonnemann et al. (2017).

The submitted mink displayed different clinical signs. Mink no. 1, a gray male of 1.4 kg, originated from a submission of four mink (10th of August 2017) from a farm in Eastern Denmark reporting of sudden deaths. Mink no. 2, a white male of 3.3 kg, originated from a submission (18th of August 2017) of six animals from a farm in Western Denmark reporting skin lesions. Mink no. 3, a white female of 1.7 kg, originated from a submission (11th of April 2018) of two animals from Western Denmark with reporting of skin lesions. In each of these three submissions, *S. phoace* was only isolated from one of the submitted animals.

The farms, from which the animals originated, were localized in different areas in Denmark. All the farms were Aleutian mink disease virus (AMDV) antibody negative, tested at Kopenhagen Fur Diagnostik according to national legislation (Anonymous, 2018). The three farms received feed from three different feed producers. There had been no known contact (e.g. trade of animals) between the three farms two years back in time from each case submission, nor had there been any trade connections with other mink farms.

The two harbor seals were found dead in October and December 2017, in two different locations along the west coast of Jutland, Denmark. Both seals were juvenile males. Seal a weighed 15.2 kg and had an identification tag from Peterburen in the Netherlands. Seal b weighed 14.5 kg and was without identification tag.

2.2. Virology

Blood samples from the three mink were tested for AMDV antibodies by fully automated ELISA at Kopenhagen Diagnostik, Kopenhagen Fur (Dam-Tuxen et al., 2014).

Lung samples from the seals were tested by real time polymerase chain reaction (RT-PCR) for influenza virus using RNeasy Mini QIAcube Kit (Qiagen, Hilden, Germany) according to Larsen et al. (2012) and for canine distemper virus by RT-PCR as previously described (Barrett et al., 1993).

2.3. Histopathology

For histology, tissue samples were taken from liver, lung, spleen, duodenum, ileum and kidney from the mink, and lung tissue was sampled from seal b. The tissue samples were fixed in 10% neutral buffered formalin, processed by routine methods for histology, embedded in paraffin wax and cut in 3–5 μm sections. The sections were mounted on conventional glass slides and stained with hematoxylin and eosin for histopathological examination (Stevens and Wilson, 1996).

2.4. Culture conditions and MALDI-TOF identification

Material from organs and tissues with lesions was used for bacteriological examination as previously described (Nonnemann et al., 2017; Nikolaisen et al., 2017). Samples were inoculated on Columbia agar supplemented with 5% calf blood and on Drigalski agar (SSI Diagnostica, Hilleroed, DK), and incubated aerobically in 37 °C for 16–20 h. When growth was detected, single colonies were subcultured on blood agar and identified by matrix-assisted laser desorption/ionization time of flight mass spectrometry (MALDI-TOF MS, Bruker Daltonics, Bremen, Germany) as previously described (Nonnemann et al., 2017). Lancefield grouping was determined using Streptex kit (Remel Europe Inc., UK).

2.5. Antimicrobial sensitivity testing

The antimicrobial sensitivity was determined using the semi-automatic system, SensiTitre (ThermoFisher Scientific) according to Clinical and Laboratory Standards Institute (CLSI, 2018), with test ranges and breakpoints as described in Nikolaisen et al. (2017).

2.6. DNA extraction

DNA extraction was performed using a Maxwell® Instrument and a LEV Cell DNA kit (Promega). The samples were prepared as follows: colony material was suspended in 1 mL phosphate buffered saline, followed by storage in −20 °C overnight. The samples were thawed and centrifuged for 10 min at 10,000 ×*g*, 5 °C. The supernatant was removed and the pellet resuspended in 300 μL lysis buffer (Promega). The resuspension was transferred to a 2 mL Eppendorf tube containing a steel bead (Stainless Steel Beads 5 mm, Qiagen), and bead-beated in a TissueLyser (Qiagen), at 20 Hz for 2 min. The samples were loaded and further processed according to the Maxwell® 16 LEV Blood DNA Kit protocol (Promega). Subsequent processing included the addition of 2 μL RNAse (2 mg/mL; Invitrogen, Easy-DNA kit) at 37 °C for 60 min, and finally DNA concentration was determined by Qubit flourometric quantification (ThermoFisher Scientific).

2.7. Whole genome sequencing and analysis

DNA was sequenced on an Illumina NextSeq in a 2 × 150 bp configuration with an expected coverage of 50×. A custom pipeline/wrapper written in bash was used for sequence analysis where two genomes from NCBI representing the type cultures of the two subspecies were included (C-4 (SAMN03114893), ATCC 51973 (SAMN03955537)). Briefly, sequencing quality was checked using fastx_quality_stats. Centrifuge was used to check for contamination (Kim et al., 2016). SPAdes was used for assembly with settings '-k 21,33,55,77 –careful' (Nurk et al., 2013). Assembly quality was checked using Quast (Seemann, 2014). Prokka was used for annotation (Mikheenko et al., 2016). Antimicrobial resistance genes (ARGs) were identified using blast with

the ResFinder database and the GFF3 file from Prokka (https://cge.cbs.dtu.dk/services/ResFinder). Putative virulence genes were identified using the Abricate package (https://github.com/tseemann/abricate) using VFBD (http://www.mgc.ac.cn/VFs/) as database and a 70% identity cut-off. Roary was used to determine the core and accessory genome and for aligning (Page et al., 2015). FastTree was used to produce a maximum-likelihood phylogenetic tree (Price et al., 2010), and further the subtree was extracted from the main tree using the subtrees-function from the R-package ape. Average Nucleotide Identity (ANI) was calculated using Pyani (https://github.com/widdowquinn/pyani). Data handling and visualization was handled in R version 3.5.1 using ggplot2 and ggtree (R Core Team, 2013).

The raw sequencing reads for each isolate have been deposited to the GenBank database under the study accession number PRJNA634223.

3. Results

3.1. Pathology and histopathology

Mink no. 1, a juvenile male, was in good nutritional condition with moderate amounts of subcutaneous and abdominal fat. In the pleural cavity, there was large amounts of red-brown exudate, i.e. pyothorax (Fig. 1A). The lungs showed compression atelectasis and chronic fibrotic pleuritis with reactive pleural mesothelium and a few accumulations of coccoid bacteria (Fig. 1B, Fig. 2AB). The finding of multifocal accumulations of coccoid bacteria in the liver sinusoids (Fig. 2C), spleen and kidney blood vessels were consistent with bacteremia. Furthermore, there was degeneration and calcification in the proximal tubular epithelium of the kidney, and moderate splenomegaly due to congestion.

Mink no. 2, an adult male, was in good nutritional condition. In the lungs, there was hyperemia and hemorrhages in the alveoli, together with massive hyperplasia of the bronchiolar associated lymphoid tissue and perivascular infiltration of mononuclear cells. The liver was congested with mild infiltration of mononuclear cells in a few portal tracts. The kidney was hyperemic with degeneration and calcification of the proximal tubular epithelium. There was mild splenomegaly. Furthermore, there was subacute suppurative pododermatitis of one digit on the right front paw.

Mink no. 3, a pregnant female, was in good nutritional condition. The lung was hyperemic with moderate perivascular infiltration of mononuclear cells and several pulmonary macrophages in the alveoli. Furthermore, there was congestion of liver and kidney, and mild splenomegaly. The skin around two digits on the left front paw was swollen due to mild diffuse infiltration of neutrophils and mononuclear cells in dermis and subcutis, together with elongation of the rete papillae (Fig. 2D). The findings were consistent with mild subacute suppurative cellulitis.

Both seals (a and b) were in poor nutritional condition with sparse subcutaneous and abdominal fat and had large numbers of endoparasites *Otostrongylus circumlitus* and *Parafilaroides* larvae in the lungs. Seal b also had suppurative bronchopneumonia with accumulations of coccoid bacteria in the lung tissue.

3.2. Microbiology

All three mink isolates of *S. phocae* were found in a mixed culture. In mink no. 1, it was found in samples from the liver, lungs and pleural fluid together with *Escherichia coli*. In mink no. 2, it was found in dermal samples from an infected digit together with *Staphylococcus schleiferi*. Samples from liver and lung were sterile. In mink no. 3, it was found in a dermal sample from an infected digit together with *Arcanobacterium phocae, Streptococcus halichoeri,* and *S. schleiferi*. Lungs and liver were sterile. All three streptococci isolates were tested as Lancefield's group C.

High numbers of *S. phocae* in mixed culture was isolated from lung tissue in seal a and b, and from liver tissue from seal a indicating presence of bacteremia in seal a.

3.3. Antimicrobial sensitivity testing

For eight of the tested antimicrobials, breakpoints for *Streptococcus* spp. were available and all isolates were sensitive (Table 1). Generally, the tested isolates had comparable MIC values. However, the MICs of the three isolates differed when tested against spectinomycin and tiamulin. The isolates from mink no. 2 and no. 3 had a high MIC value when tested against spectinomycin and tiamulin compared to the others (Table 1, Supplementary Table 1). The spectinomycin values were above cut-off value (>32 μg/mL) reported for *Streptococcus canis* isolated from mink (Nikolaisen et al., 2020). The two isolates from seals seemed generally sensitive to all tested antimicrobials.

3.4. Virology

All three mink tested negative for AMDV antibodies. Further, the farms from which the animals originated were AMVD antibody negative.

The two seals tested negative for influenza virus and distemper virus.

3.5. Whole genome sequencing and analysis

Five *S. phocae* isolates from each of the three mink and the two seals were whole-genome sequenced to determine their genetic relatedness. Additionally, the two existing *S. phocae* assemblies from NCBI were included for reference with one being *S. phocae* subsp. *salmonis* from a diseased salmon, C-4^{T}, and the other from the liver of a seal, which is the *S. phocae* subsp. *phocae* type culture, ATCC 51973^{T}, from the original

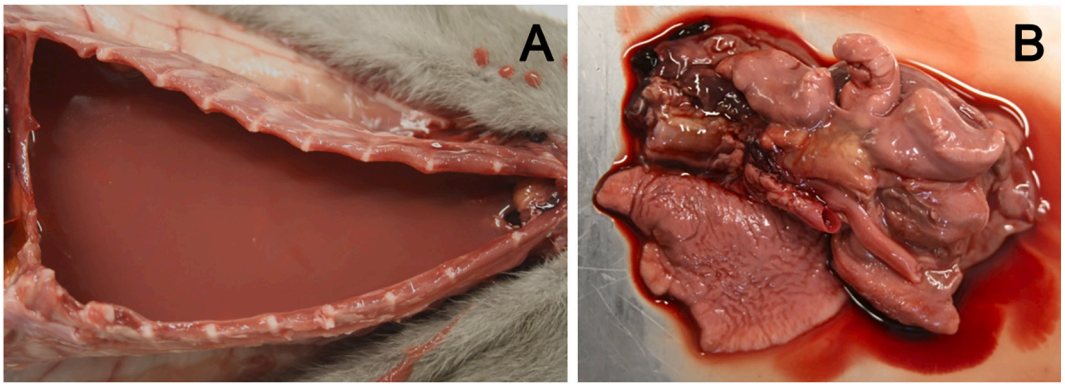

Fig. 1. Mink no. 1. A) Ventral part of thorax removed, pleural cavity filled with red-brown exudate consistent with pyothorax. B) Compression atelectasis of lungs. (For interpretation of the references to colour in this figure legend, the reader is referred to the web version of this article.)

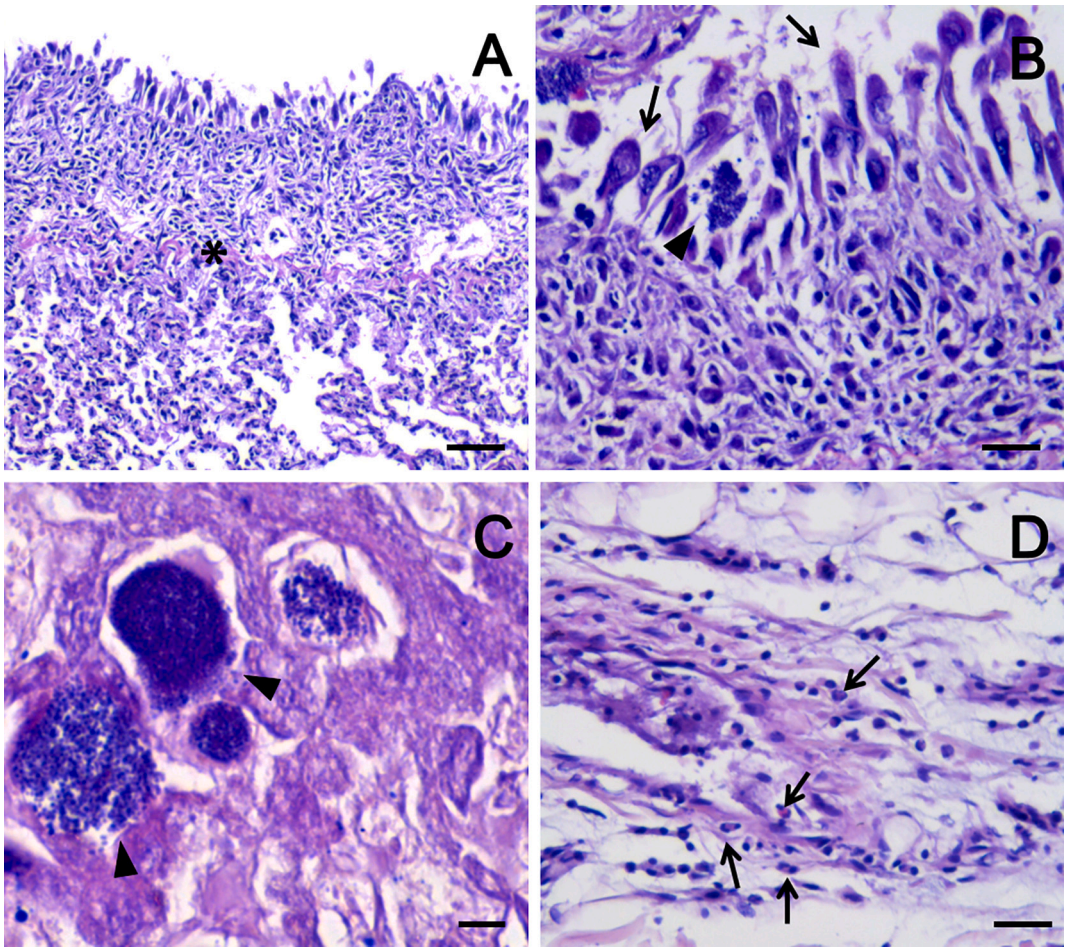

Fig. 2. A–C: Mink no. 1. A) Massive chronic fibrotic pleuritis. Asterisk marks the elastic fibers of the visceral pleura, with normal lung tissue below. Scalebar 50 μm, HE; B) Hypertrophic and reactive pleural mesothelium (arrow) and accumulations of coccoid bacteria (arrowhead). Scalebar 25 μm, HE; C) Accumulations of coccoid bacteria (arrowhead) in liver sinusoids consistent with bacteremia. Scalebar 10 μm, HE; D) Mink no. 3. Mild diffuse infiltration of neutrophils (arrow) and mononuclear cells in dermis and subcutis consistent with mild subacute suppurative cellulitis. Scalebar 10 μm, HE.

Table 1
MIC distribution and occurrence of resistance of three *Streptococcus phocae* isolates from Danish mink.

	Minimal inhibitory concentration (MIC) distribution (μg/ml)														
	0.063	0.125	0.25	0.5	1	2	4	8	16	32	64	128	256	512	1024
Cefoxitin					x o	z									
Chloramphenicol						x o z									
Ciprofloxacin				x z	o										
Erythromycin			x o z												
Florfenicol					x o z										
Gentamicin					o z		x								
Penicillin	x o z														
Spectinomycin									x					o z	
Streptomycin									x o z						
Sulfamethoxazole										x o z					
Tetracycline				x o z											
Tiamulin			x							z	o				
TMP+sulfa			x o z												
Trimethoprim				x z	o										

x: Mink no. 1, septic case from the east of Denmark, 2017, o: Mink no. 2, dermal case from the west of Denmark, 2017, z: Mink no. 3, dermal case from the west of Denmark, 2018. The vertical lines indicate breakpoints (*Streptococcus* spp., adapted from Nikolaisen et al., 2017). The test range is indicated by white fields. Values above the test range, are here given as one concentration higher than the range. MICs in the lowest concentration of the test range are below or equal to. TMP + sulfa: Trimethoprim in combination with sulfamethoxazole (1:19).

description from Skaar et al. (1994). The average GC-content was 39.47% (SD = 0.092%) and a mean assembly length of 1.687 Mb (SD = 65.5 kb) in line with the references.

The core genome, defined as the genes that all isolates had in common, was 1267 genes. The accessory genome was comprised of 1266 genes found in at least one of the analyzed isolates.

Four (the three from mink and one from a seal) *S. phocae* isolates were closely related with at most 30 SNPs in-between them. These isolates formed a separate cluster, although closest related to the *S. phocae* subsp. *phocae* type strain. The other seal isolate was distantly related 22,500 SNPs (Fig. 3) and was closest related to the subsp. *phocae* type strain. The two most closely related were mink no. 2 and mink no. 3 with 12 SNPs in-between them. The two reference assemblies also showed large differences to the rest of the isolates (Fig. 3).

A pairwise average nucleotide identity (ANI) analysis was performed. The results are summarized in Supplementary Fig. 2. The ANI confirmed that the isolate from seal a genomically was located between the two type strains. However, the isolates from the three mink and from seal b were closely related and clustered together outside the other strains. It may be suggested that they may constitute a separate subspecies, however this needs to be further analyzed.

A hemolysin-like protein 98–100% identical to *tlyA* in *Streptococcus dysgalactiae* was identified in all isolates in concordance with hemolysis in blood plates. Furthermore, 74 genes were only found in the isolates from the mink, most of them identified as hypothetical proteins. Among the non-hypothetical proteins were conjugal transfer, mobilization, relaxase, and DNA primase proteins hinting at a possible pathogenicity island or a plasmid. All five isolates had *comEA* and *comEC* genes, which both are connected to DNA uptake. Other putative virulence factors that were found in the isolates were genes with high similarity to genes found in other *Streptococcus* species. All isolates carried a gene with high similarity to the *fbp54* gene encoding a fibronectin binding protein described in *Streptococcus pyogenes*, the *hasC* gene encoding UDP-glucose pyrophosphorylase described in *S. pyogenes*, and the *psaA* gene encoding a manganese-binding adhesion lipoprotein described in *Streptococcus pneumoniae* (Supplementary Table 2). The four isolates from mink 1–3 and from seal b all carried a gene with high similarity to the *sda* gene encoding streptodornase, found in *S. pyogenes*, while the two type cultures both carried a gene, *slo*, with high homology to streptolysin in *S. pyogenes* (Supplementary Table 2).

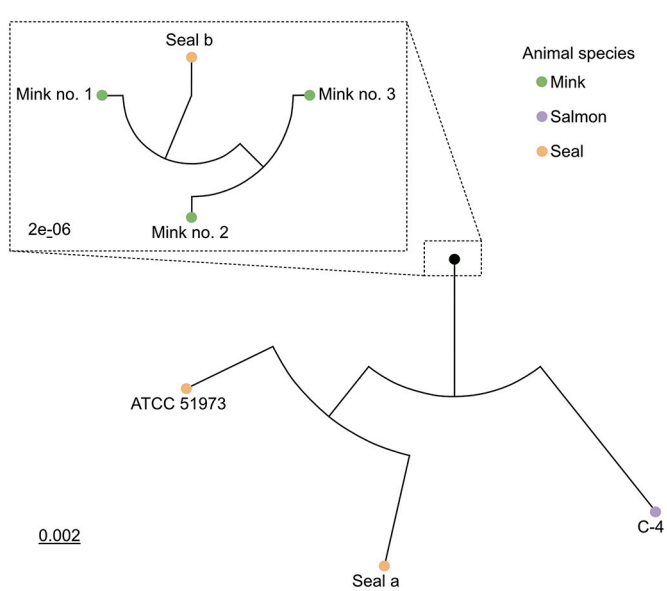

Fig. 3. Maximum-likelihood phylogenetic trees. The middle tree depicts all the isolates including references, whereas the small tree represents the closely related isolates. Scale bars represent nucleotide substitutions per nucleotide.

Three putative antimicrobial resistance genes (ARGs) were identified in each of two of the five sequenced isolates (mink no. 2 and 3); *lnu(B)*, a lincosamide nucleotidyltransferase, *lsa(E)*, a putative ABC transporter, and *ant1/aad(9)*, a streptomycin 3″-adenylyltransferase. The regions containing the ARGs were 100% identical between the isolates, this including placement of the ARGs and non-ARGs. Additionally, the three ARGs were found in close proximity of each other on their respective contigs (Supplementary Fig. 1). Further upstream, a putative conjugative transposase protein belonging to the *Tn*916-family was found. This region also showed a high degree of similarity (>99% identity) to a 12 kb region found in *Streptococcus suis*, strain nc286A7 transposon integrative conjugative element ICESsuNC286 (KU215704.1). The isolates from mink no. 2 and mink no. 3 were also the only ones found to be resistant to spectinomycin and tiamulin.

4. Discussion

Mink is a semiaquatic mustelid. However, in the present study, the mink from which *S. phocae* was isolated were all farmed. Therefore, they had not been in contact with an aquatic habitat, as opposed to previous reports of *S. phocae* isolated from other animals, which all have been wildlife species. Danish mink farms have a strong biosecurity with fences to avoid escapes of farmed mink to the nature and to control wildlife in the farm area (Anonymous, 2015). However, birds are not controlled and could potentially be a source of introduction of bacteria. Another route of introduction to be considered is the feed, as mink feed includes fish and fish by-products (Lyhs et al., 2019). However, the isolates from mink were not particularly closely related to the subspecies *salmonis* C-4 although closer than to the subspecies *phocae* type strain (Fig. 3).

Two of the mink cases described here were diagnosed with dermal infections. Purulent dermal infections in mink have also been associated with *Arcanobacterium phocae*, which is assumed to be causative agent of fur animal epidemic necrotic pyoderma (FENP) (Nordgren et al., 2014). This bacterial species was recently described as the cause of serious outbreaks of disease in Danish mink farms (Nonnemann et al., 2017). Due to the similarity in both host spectrum and pathological manifestations, it may be speculated whether the bacteria share route of entry to the farms. In addition, bacteremia/septicemia was seen in one of the mink and one of the seals, which points out the pathological potential of *S. phocae*.

The antimicrobial sensitivity testing showed that all three *S. phocae* isolates were sensitive to the majority of the tested antimicrobials (Table 1). The three isolates were sensitive to penicillin, which corresponds with previous findings of sensitive beta-hemolytic streptococci in mink (Nikolaisen et al., 2017). Penicillin is a narrow spectrum beta-lactam and the susceptibility of these pathogens is hence important for future treatment and prudent use of antimicrobials.

The whole genome sequencing results revealed ARGs in two out of three mink isolates, these ARGs were placed in a 100% identical region. This could indicate that the region is mobile and transferable or at least that it has been. Additionally, the region was nearly identical to an integrative and conjugational element (ICE) found in *Streptococcus suis*, a major pathogen in the swine industry (Gottschalk et al., 2010, Huang et al., 2016). *Streptococcus* spp. are often naturally competent, have a large pan-genome and have been shown to transfer genetic material between species of the genus (Shelyakin et al., 2019). Previously, it was found that the livestock-associated methicillin resistant *Staphylococcus aureus* (LA-MRSA) found in Danish mink farms are closely related to the LA-MRSA found in Danish pig farms, which could be explained by introduction of contaminated pig by-products into the mink farms (Fertner et al., 2019). One could thus speculate whether an introduction of *S. suis* from pigs into mink farms have facilitated a transfer of the aforementioned ICE into *S. phocae* resulting in resistance to spectinomycin and tiamulin. This is supported by the observation that all five isolates had *comEA* and *comEC* genes which can facilitate natural competence (Chen and Dubnau, 2004).

Sequencing results might indicate that either a subgroup of *S. phocae* is able to cause disease in mink or that there has been a single introduction of *S. phocae* in mink. However, the WGS analysis revealed that the seal isolates are diverse and places one isolate from a seal in close relation to the three mink isolates and the other seal isolate between the two subspecies type strains (Fig. 3). Further investigations are needed to clarify this connection and whether the mink isolates should be referred to any of the two subspecies or rather to a new subspecies.

All *S. phocae* isolates carried genes with homology to virulence genes known from other *Streptococcus* species. FBP54 encoded by the *fbp54* gene is a 54 kDa fibronectin-binding protein, which mediates adhesion of *S. pyogenes* to fibronectin on e.g. buccal epithelium in humans and thereby facilitates colonization (Courtney et al., 1996). Pneumococcal surface antigen A, PsaA encoded by the *psaA* gene, is a lipoprotein, which mediates transportation of Mn^{2+} and Zn^{2+} in *S. pneumoniae*. These two ions are essential cofactors for various bacterial metabolic enzymes and proteins, and therefore PsaA is essential for the survival and growth of *S. pneumoniae*, especially during infection of a host where access to these ions can be limited by host mechanisms (Li et al., 2014). The *hasC* gene in *S. pyogenes* encodes UDP-glucose pyrophosphorylase, an enzyme which synthetizes UDP-glucose from UTP and glucose-1-phosphate. It is part of the *has ABC* gene cluster, which is responsible for the synthesis of a hyaluronic acid capsule in pneumococci (Ashbaugh et al., 1998). Such a capsule is important for the bacterial virulence by protecting is against host defense mechanisms. The presence of the homologues of these three genes in *S. phocae* is interesting but their function remains to be investigated. Another interesting observation was the presence of a gene in the mink isolates and seal b with high homology to the *sda* gene found in *S. pyogenes* and also other hemolytic streptococci. This gene encodes streptodornase, which is a deoxyribonuclease that causes hydrolysis of DNA and deoxyribonucleoprotein outside of living cells and also in the nuclei of degenerating cells, and it also dissolves pus (https://www.merriam-webster.com/medical/streptodornase). Another virulence factor, streptolysin, was only found in the two type cultures and not in any of the mink or seal isolates. Streptodornase and streptolysin were also detected by Bethke and Avendaño-Herrera (2017) in their investigation of sequencing of the two type cultures.

5. Conclusion

Streptococcus phocae has in other species been described as an emerging pathogen, therefore future awareness and surveillance of this pathogen is crucial. This is the first reported finding of *S. phocae* isolated from farmed mink. Further investigation is needed to conclude whether *S. phocae* is establishing as commensal in mink. Sequence data revealed a higher diversity within the species that hitherto known and the mink isolates were closely related to each other and to an isolate from a seal, but not to any of the two subspecies type strains. The mink isolates shared virulence factors with other pathogenic streptococci. Both the precise taxonomic position and the function of virulence factors in *S. phocae* from mink needs further clarification.

Supplementary data to this article can be found online at https://doi.org/10.1016/j.rvsc.2021.07.015.

Funding

The project was funded by Pelsdyrafgiftsfonden and Dansk Pelsdyravlerforeningens Forskningsfond.

Acknowledgements

The authors sincerely acknowledge all the highly skilled assistance of technicians and veterinarians at the (former) National Veterinary Institute at the Technical University of Denmark. A sincere thanks to Dr. Tim Kåre Jensen (Center for Diagnostics, Technical University of Denmark) for his assistance with the preparation of histopathological slides.

References

Anonymous, 2015. Bekendtgørelse om husning af mink og hegning af minkfarme. BEK nr. 1422 af 03/12/2015. https://www.retsinformation.dk/eli/lta/2015/1422 (Accessed 02 Dec 2019).

Anonymous, 2018. Bekendtgørelse om plasmacytose hos pelsdyr. BEK nr. 1280 af 14/11/2018. https://www.retsinformation.dk/eli/lta/2018/1280 (Accessed 02 Dec 2019).

Ashbaugh, C.D., Albertí, S., Wessels, M.R., 1998. Molecular analysis of the capsule gene region of group a *Streptococcus*: the *hasAB* genes are sufficient for capsule expression. J. Bacteriol. 180, 4955–4959.

Avendaño-Herrera, R., Suarez, R., Lazo, E., Bravo, D., Llegues, K.O., Romalde, J.L., 2014. Genome sequence of *Streptococcus phocae* subsp. *salmonis* strain C-4T, isolated from atlantic salmon (*Salmo salar*). Genome Announc. 2, 8–9. https://doi.org/10.1128/genomeA.01269-14.

Barrett, T., Visser, I.K., Mamaev, L., Goatley, L., van Bressem, M.F., Osterhaus, A.D., 1993. Dolphin and porpoise morbilliviruses are genetically distinct from phocine distemper virus. Virology 193, 1010–1012.

Bethke, J., Avendaño-Herrera, R., 2017. Comparative genome analysis of two *Streptococcus phocae* subspecies provides novel insights into pathogenicity. Mar. Genomics 31, 53–61. https://doi.org/10.1016/j.margen.2016.09.005.

Chen, I., Dubnau, D., 2004. DNA uptake during bacterial transformation. Nat. Rev. Microbiol. 2, 241–249. https://doi.org/10.1038/nrmicro844.

Clinical and Laboratory Standards Institute, 2018. Performance Standards for Antimicrobial Disk and Dilution Susceptibility Tests for Bacteria Isolated From Animals, 5th ed. CLSI VET01, Wayne, PA.

Courtney, H.S., Dale, J.B., Hasty, D.I., 1996. Differential effects of the streptococcal fibronectin-binding protein, FBP54, on adhesion of group A streptococci to human buccal cells and HEp-2 tissue culture cells. Infect. Immun. 64, 2415–2419.

Dam-Tuxen, R., Dahl, J., Jensen, T.H., Dam-Tuxen, T., Struve, T., Bruun, L., 2014. Diagnosing Aleutian mink disease infection by a new fully automated ELISA or by counter current immunoelectrophoresis: a comparison of sensitivity and specificity. J. Virol. Methods 199, 53–60. https://doi.org/10.1016/j.jviromet.2014.01.011.

Fertner, M., Pedersen, K., Jensen, V.F., Larsen, H., Larsen, G., Lindegaaard, M., Hansen, J.E., Chriél, M., 2019. Within-farm prevalence and environmental distribution of livestock-associated methicillin-resistant *Staphylococcus aureus* in farmed mink (*Neovison vison*). Vet. Microbiol. 231, 80–86. https://doi.org/10.1016/j.vetmic.2019.02.032.

Gibello, A., Mata, A.I., Blanco, M.M., Casamayor, A., Domínguez, L., Fernandez-Garayzabal, J.F., 2005. First identification of *Streptococcus phocae* isolated from Atlantic salmon (*Salmo salar*). J. Clin. Microbiol. 43, 526–527. https://doi.org/10.1128/JCM.43.1.526.

Gottschalk, M., Xu, J., Calzas, C., Segura, M., 2010. *Streptococcus suis*: a new emerging or an old neglected zoonotic pathogen? Future Microbiol. 5 (3), 371–391. https://doi.org/10.2217/fmb.10.2.

Henton, M.M., Zapke, O., Basson, P.A., 1999. *Streptococcus phocae* infections associated with starvation in cape fur seals. J. S. Afr. Vet. Assoc. 70, 98–99. https://doi.org/10.4102/jsava.v70i2.763.

Huang, K., Zhang, Q., Song, Y., Zhang, Z., Zhang, A., Xiao, J., Jin, M., 2016. Characterization of spectinomycin resistance in *Streptococcus suis* leads to two novel insights into drug resistance formation and dissemination mechanism. Antimicrob. Agents Chemother. 60 (10), 6390–6392. https://doi.org/10.1128/AAC.01157-16.

Hueffer, K., Lieske, C.L., McGilvary, L.M., Hare, R.F., Miller, D.L., O'Hara, T.M., 2011. *Streptococcus phocae* isolated from a spotted seal (*Phoca largha*) with pyometra in Alaska. J. Zoo. Wildl. Med. 42, 108–112. https://doi.org/10.1638/2010-0064.1.

Imai, D., Jang, S., Miller, M., Conrad, P.A., 2009. Characterization of beta-hemolytic streptococci isolated from southern sea otters (*Enhydra lutris nereis*) stranded along the California coast. Vet. Microbiol. 136, 378–381. https://doi.org/10.1016/j.vetmic.2008.11.009.

Johnson, S., Lowenstine, L., Gulland, F., Jang, S., Imai, D., Almy, F., DeLong, R., Gardner, I., 2006. Aerobic bacterial flora of the vagina and prepuce of California Sea lions (*Zalophus californianus*) and investigation of associations with urogenital carcinoma. Vet. Microbiol. 114, 94–103. https://doi.org/10.1016/j.vetmic.2005.11.045.

Kim, D., Song, L., Breitwieser, F.P., Salzberg, S.L., 2016. Centrifuge: rapid and sensitive classification of metagenomic sequences. Genome Res. 26, 1721–1729. https://doi.org/10.1101/gr.210641.116.

Kuiken, T., Kennedy, S., Barrett, T., Van De Bildt, M.W.G., Borgsteede, F.H., Brew, S.D., Codd, G.A., Duck, C., Deaville, R., Eybatov, T., Forsyth, M.A., Foster, G., Jepson, P.D., Kydyrmanov, A., Mitrofanov, I., Ward, C.J., Wilson, S., Osterhaus, A.D.M.E., 2006. The 2000 canine distemper epidemic in Caspian seals (*Phoca caspica*): pathology and analysis of contributory factors. Vet. Pathol. 43, 321–338.

Larsen, L.E., Breum, S.Ø., Trebbien, R., Bradstad, K., Nielsen, L.P., Chriél, M., Jensen, T.H., Hjulsager, C.K., Handberg, K., Jørgensen, P.H., Le Févre Harslund, J., Rangstrup-Christensen, L., Pedersen, B., Hammer, A.S., 2012. Outbreaks of influenza A virus in farmed mink (Neovison vison) in Denmark: molecular characterization of the viruses. In: Proceedings of the X International Scientific Congress in Fur Animal Production. Larsen, P.F., Møller, S.H.., Clausen, T., Hammer, A.S., Lássen, T.M., Nielsen VH, Tauson, A.H. (Eds), Wageningen Academic Publishers, The Netherlands; 2012.

Li, N., Yang, X.-Y., Guo, Z., Zhang, J., Cao, K., Han, J., Zhang, J., Liu, L., Sun, X., He, Q.-Y., 2014. Varied metal-binding properties of lipoprotein PsaA in *Streptococcus*

pneumoniae. J. Biol. Inorg. Chem. 19, 829–838. https://doi.org/10.1007/s00775-014-1114-9.

Lyhs, U., Frandsen, H., Andersen, B., Nonnemann, B., Hjulsager, C., Pedersen, K., Chriél, M., 2019. Microbiological quality of mink feed raw materials and feed production area. Acta Vet. Scand. 61, 56. https://doi.org/10.1186/s13028-019-0489-6.

Mikheenko, A., Valin, G., Prjibelski, A., Saveliev, V., Gurevich, A., 2016. Icarus: visualizer for de novo assembly evaluation. Bioinformatics 32, 3321–3323. https://doi.org/10.1093/bioinformatics/btw379.

Nikolaisen, N.K., Lassen, D.C.K., Chriél, M., Larsen, G., Jensen, V.F., Pedersen, K., 2017. Antimicrobial resistance among pathogenic bacteria from mink (*Neovison vison*) in Denmark. Acta Vet. Scand. 59, 60. https://doi.org/10.1186/s13028-017-0328-6.

Nikolaisen, N.K., Ronaghinia, A.A., Lassen, D.C.K., Chehabi, C.N., Lindegaard, M., Struve, T., Chriél, M., Damborg, P., Kahlmeter, G., Jensen, L.B., Pedersen, K., 2020. Employing MIC data for mink pathogens to propose tentative epidemiological cut-off values: a step toward rationalizing antimicrobial use in mink. Front. Vet. Sci. 7, 544594. https://doi.org/10.3389/fvets.2020.544594.

Nonnemann, B., Chriél, M., Larsen, G., Hansen, M.S., Holm, E., Pedersen, K., 2017. Arcanobacterium phocae infection in mink (*Neovison vison*), seals (*Phoca vitulina, Halichoerus grypus*) and otters (*Lutra lutra*). Acta Vet. Scand. 59, 74. https://doi.org/10.1186/s13028-017-0342-8.

Nordgren, H., Aaltonen, K., Sironen, T., Kinnunen, P.M., Kivistö, I., Raunio-Saarnisto, M., Moisander-Jylhä, A.M., Korpela, J., Kokkonen, U.M., Hetzel, U., Sukura, A., Vapalahti, O., 2014. Characterization of a new epidemic necrotic pyoderma in fur animals and its association with *Arcanobacterium phocae* infection. PLoS One 9. https://doi.org/10.1371/journal.pone.0110210.

Nurk, S., Bankevich, A., Antipov, D., Gurevich, A., Korobeynikov, A., Lapidus, A., Prjibelsky, A., Pyshkin, A., Sirotkin, A., Sirotkin, Y., Stepanauskas, R., McLean, J., Lasken, R., Clingenpeel, S.R., Woyke, T., Tesler, G., Alekseyev, M.A., Pevzner, P.A., 2013. Assembling genomes and mini-metagenomes from highly chimeric reads. In: Deng, M., Jiang, R., Sun, F., Zhang, X. (Eds.), Research in Computational Molecular Biology. Springer, Berlin Heidelberg, Berlin, Heidelberg, pp. 158–170.

Page, A.J., Cummins, C.A., Hunt, M., Wong, V.K., Reuter, S., Holden, M.T.G., Fookes, M., Falush, D., Keane, J.A., Parkhill, J., 2015. Roary: rapid large-scale prokaryote pan genome analysis. Bioinformatics 31, (22) 3691–3693. doi:10.1093/bioinformatics/btv421.

Price, M.N., Dehal, P.S., Arkin, A.P., 2010. FastTree 2 - approximately maximum-likelihood trees for large alignments. PLoS One 5. https://doi.org/10.1371/journal.pone.0009490.

R Core Team, 2013. R: a language and environment for statistical computing. In: R Foundation for Statistical Computing, Vienna, Austria. URL. http://www.R-project.org/.

Raverty, S.A., Gaydos, J.K., Nielsen, O., Ross, P.S., 2004. Pathologic and Clinical Implications of *Streptococcus phocae* Isolated from Pinnipeds Along Coastal Washington State, British Columbia, and Arctic Canada. Abstracts of the 35th Annual Conference of the International Association of Aquatic Animal Medicine, Galveston, TX, April 2004. IAAAM.

Romalde, J.L., Ravelo, C., Valdés, I., Magariños, B., de la Fuente, E., Martín, C.S., Avendaño-Herrera, R., Toranzo, A.E., 2008. *Streptococcus phocae*, an emerging pathogen for salmonid culture. Vet. Microbiol. 130, 198–207. https://doi.org/10.1016/j.vetmic.2007.12.021.

Seemann, T., 2014. Prokka: rapid prokaryotic genome annotation. Bioinformatics 30, 2068–2069. https://doi.org/10.1093/bioinformatics/btu153.

Shelyakin, P., Bochkareva, O., Karan, A., Gelfand, M.S., 2019. Micro-evolution of three *Streptococcus* species: selection, antigenic variation, and horizontal gene inflow. BMC Evol. Biol. 19 (83), 20. https://doi.org/10.1186/s12862-019-1403-6.

Skaar, I., Gaustad, P., Holm, B., Stenwig, H., 1994. *Streptococcus phocae* sp. *nov.*, a new species isolated from clinical specimens from seals. Int. J. Syst. Evol. Microbiol. 44, 646–650.

Stevens, A., Wilson, I., 1996. The haematoxylins and eosin. In: Bancroft, J.D., Stevens, A. (Eds.), Theory Pract. Histol. Tech, , 4th ed.1996. Churchill Livingstone, Medical Division of Pearson Professional Limited, pp. 99–112.

Taurisano, N.D., Butler, B.P., Stone, D., Hariharan, H., Fields, P.J., Ferguson, H.W., Haulena, M., Cotrell, P., Nielsen, O., Raverty, S., 2018. *Streptococcus phocae* in marine mammals of northeastern Pacific and Arctic Canada: a retrospective analysis of 85 postmortem investigations. J. Wildl. Dis. 54 https://doi.org/10.7589/2016-09-208, 2016-09–208.

Vossen, A., Abdulmawjood, A., Lämmler, C., Weiß, R., Siebert, U., 2004. Identification and molecular characterization of beta-hemolytic streptococci isolated from harbour seals (*Phoca vitulina*) and Grey Seals (*Halichoerus grypus*) of the German orth and Baltic seas. J. Clin. Microbiol. 42, 469–473. https://doi.org/10.1128/JCM.42.1.469-473.2004.