



Computed Tomography as a Method for Age Determination of Carnivora and Odontocetes with Validation from Individuals with Known Age

Baier-Stegmaier, Sina; Gundlach, Carsten; Chriél, Mariann; Hansen, Mette Sif; Vedel-Smith, Christina; Hansen, Charlotte Vikkelsø; Johansson, Daniel Klingberg; Henriksen, Louise Birgitte; Wahlberg, Magnus; Thøstesen, Charlotte Bie

Total number of authors:
14

Published in:
Animals

Link to article, DOI:
[10.3390/ani13111783](https://doi.org/10.3390/ani13111783)

Publication date:
2023

Document Version
Publisher's PDF, also known as Version of record

[Link back to DTU Orbit](#)

Citation (APA):

Baier-Stegmaier, S., Gundlach, C., Chriél, M., Hansen, M. S., Vedel-Smith, C., Hansen, C. V., Johansson, D. K., Henriksen, L. B., Wahlberg, M., Thøstesen, C. B., Alstrup, A. K. O., Gregersen, K. M., Pertoldi, C., & Pagh, S. (2023). Computed Tomography as a Method for Age Determination of Carnivora and Odontocetes with Validation from Individuals with Known Age. *Animals*, 13(11), Article 1783. <https://doi.org/10.3390/ani13111783>

General rights

Copyright and moral rights for the publications made accessible in the public portal are retained by the authors and/or other copyright owners and it is a condition of accessing publications that users recognise and abide by the legal requirements associated with these rights.

- Users may download and print one copy of any publication from the public portal for the purpose of private study or research.
- You may not further distribute the material or use it for any profit-making activity or commercial gain
- You may freely distribute the URL identifying the publication in the public portal

If you believe that this document breaches copyright please contact us providing details, and we will remove access to the work immediately and investigate your claim.

Computed Tomography as a Method for Age Determination of Carnivora and Odontocetes with Validation from Individuals with Known Age

Sina Baier-Stegmaier ¹, Carsten Gundlach ¹, Mariann Chriél ², Mette Sif Hansen ^{2,3} , Christina Vedel-Smith ⁴, Charlotte Vikkelsø Hansen ⁴, Daniel Klingberg Johansson ⁵, Louise Birgitte Henriksen ⁶, Magnus Wahlberg ⁷, Charlotte Bie Thøstesen ⁸ , Aage Kristian Olsen Alstrup ^{9,10} , Kristian Murphy Gregersen ¹¹ , Cino Pertoldi ¹²  and Sussie Pagh ^{12,*} 

¹ Department of Physics, Technical University of Denmark, 2800 Kongens Lyngby, Denmark; sbaier@fysik.dtu.dk (S.B.-S.)

² Department of Health Technology Center for Diagnostics, Technical University of Denmark, 2800 Kongens Lyngby, Denmark

³ Department of Veterinary and Animal Sciences, University of Copenhagen, 1870 Frederiksberg C, Denmark

⁴ Department of Research and Collections, Natural History Museum Aarhus, 8000 Aarhus, Denmark; cvs@nathist.dk (C.V.-S.)

⁵ Natural History Museum of Denmark, University of Copenhagen, 1165 København, Denmark

⁶ Department of Biology, University of Southern Denmark, 5230 Odense, Denmark

⁷ Marine Biological Research Center, University of Southern Denmark, 5300 Kerteminde, Denmark

⁸ The Fisheries and Maritime Museum, 6710 Esbjerg, Denmark

⁹ Department of Clinical Medicine, Aarhus University, 8200 Aarhus, Denmark

¹⁰ Department for Nuclear Medicine & PET, Aarhus University Hospital, 8200 Aarhus, Denmark

¹¹ Institute of Conservation, Royal Danish Academy, 1435 København, Denmark

¹² Department of Chemistry and Bioscience—Section of Biology and Environmental Science, Aalborg University, 9220 Aalborg, Denmark

* Correspondence: sup@bio.aau.dk



Citation: Baier-Stegmaier, S.; Gundlach, C.; Chriél, M.; Hansen, M.S.; Vedel-Smith, C.; Hansen, C.V.; Johansson, D.K.; Henriksen, L.B.; Wahlberg, M.; Thøstesen, C.B.; et al. Computed Tomography as a Method for Age Determination of Carnivora and Odontocetes with Validation from Individuals with Known Age. *Animals* **2023**, *13*, 1783. <https://doi.org/10.3390/ani13111783>

Academic Editors: Víctor Colino-Rabanal and Miguel Lizana

Received: 22 April 2023

Revised: 19 May 2023

Accepted: 24 May 2023

Published: 27 May 2023



Copyright: © 2023 by the authors. Licensee MDPI, Basel, Switzerland. This article is an open access article distributed under the terms and conditions of the Creative Commons Attribution (CC BY) license (<https://creativecommons.org/licenses/by/4.0/>).

Simple Summary: Especially when it comes to ancient and valuable museum samples of rare or extinct species, non-invasive methods for aging specimens are preferable. X-ray micro-computed tomography (μ -CT) is considered a non-invasive technique for age determination of mammalian carnivores and toothed whales. Teeth from 13 red foxes (*Vulpes vulpes*), 2 American mink (*Neogale vison*), and 2 harbor porpoises (*Phocoena phocoena*) of known age were examined using μ -CT. The number of visible dental growth layers extracted from the μ -CT data was highly correlated with the true age of the individuals for all three species.

Abstract: Traditional methods for age determination of wildlife include either slicing thin sections off or grinding a tooth, both of which are laborious and invasive. Especially when it comes to ancient and valuable museum samples of rare or extinct species, non-invasive methods are preferable. In this study, X-ray micro-computed tomography (μ -CT) was verified as an alternative non-invasive method for age determination of three species within the order of Carnivora and suborders Odontoceti. Teeth from 13 red foxes (*Vulpes vulpes*), 2 American mink (*Neogale vison*), and 2 harbor porpoises (*Phocoena phocoena*) of known age were studied using μ -CT. The number of visible dental growth layers in the μ -CT were highly correlated with true age for all three species ($R^2 = 96\%$, $p < 0.001$). In addition, the Bland–Altman plot showed high agreement between the age of individuals and visible dental layers represented in 2D slices of the 3D μ -CT images. The true age of individuals was on average 0.3 (± 0.6 SD) years higher than the age interpreted by the μ -CT image, and there was a 95% agreement between the true age and the age interpreted from visible dental layers in the μ -CT.

Keywords: museum collections; X-ray; computed tomography; micro-CT; μ -CT; toothed whale age; carnivore age; red fox; *Vulpes vulpes*; American mink; *Neogale vison*; harbor porpoise; *Phocoena phocoena*

1. Introduction

Age determination is crucial for population studies (e.g., demography, life tables, mortality, age-related reproduction, cause of death, body size, and asexual dimorphism) [1–10]. Several methods have been explored to determine the age of mammalian carnivores and toothed whales (e.g., cranial dimensions, dry weight of eye lenses, degree of fusion of cranial sutures, occlusion of the pulp cavity, or increments in dentine layers) [11–18]. With such methods, juveniles can be separated from adults, but they can only provide an approximate age of the individual.

Dental layer counting is widely accepted as the standard method for determining the age of mammalian carnivores and toothed whales [11,19,20]. The development of a pulp cavity (which is wider in young animals) and dentine layers are species-specific. In carnivores and toothed whales, one dentine layer is normally formed each year [12,21,22]. In general, the cementum lines in individuals from the families Canidae and Mustelidae are found in the tooth root outermost from the neonatal line (the line separating the primary and secondary dental layer) where each line represents one year [12,21]. In contrast, dental growth layer groups (GLGs; several thin groups of layers) in toothed whales are counted in the dentine crown on the inside of the neonatal line [17,18,22].

For mammalian carnivores and toothed whales, the tooth-preparation methods vary to some extent. In the most often used treatment, a tooth is decalcified for 2–48 h, after which it is sliced in thin sections of 20–30 μm with a microtome, stained with tissue color, and mounted on object glass before the age lines are visible and can be counted [1,11,17–20,23]. Alternatively, teeth are ground roughly to half their thickness using sandpaper and then smoothened and finally polished [20,24].

Once the dental layers are visible, they can be counted under a stereo microscope (sometimes iteratively because some layers may be more visible at different focal depths). Although this is a common procedure for determining the age of mammal carnivores and toothed whales, the process is to some extent prone to errors due to subjectivity of the person performing the work [21]. Most of all, in all the traditional methods it is necessary to split the tooth into half to determine the age of the individual. This is especially challenging when studying valuable museum collections of rare or extinct species or fossils of younger age. An example of the potential use of some features in fossil carnivoran teeth was recently mentioned [25].

An alternative and non-invasive technique is X-ray micro-computed tomography ($\mu\text{-CT}$). $\mu\text{-CT}$ scans allow us to obtain a full 3D image of the studied object, which can be used to digitally preserve the object, virtually cut the object at different angles and study the resulting 2D slices, and measure various desired parameters. The contrast is based on different X-ray absorption properties of the material depending on differences in the density and atomic number of the investigated material. Thus, a material with a higher atomic number or density appears brighter in the final 3D image than a material with a lower atomic number or density. Earlier attempts at age determination with structurally non-invasive techniques such as magnetic resonance imaging (MRI) and X-ray CT have not been successful [26,27]. However, Velasco et al. [28] used synchrotron-based X-ray CT for successful visualization of dental lines in the cementum of three species of African bovids.

The aim of this study was to test X-ray $\mu\text{-CT}$ as a tool to read the dental lines of animals from two species within the order Carnivora and one species within the suborder Odontoceti and to compare layers found in the dental cementum with the known age of the individuals.

2. Materials and Methods

X-ray $\mu\text{-CT}$ was conducted on teeth and roots from individuals of known age of the three species: red foxes (*Vulpes vulpes*) ($n = 13$), American mink (*Neogale vison*) ($n = 2$), and harbor porpoises (*Phocoena phocoena*) ($n = 2$). We used the canine teeth of mink and foxes (largest teeth) because they were the easiest to handle. Porpoise teeth are all alike in their shape and size (homodont). For further analysis and visualization, the software “Avizo

Lite 2020.20" (Thermo Fisher Scientific, Waltham, MA, USA) was used. Hereafter, red fox, American mink, and harbor porpoise are referred to as fox, mink and porpoise.

The teeth of 13 fox skeletons of known age were stored at The Natural History Museum of Aarhus (NHM 13,000 to 13,202 from the museum's collection) for around 50 years. The foxes had been ear-tagged as cubs from 1965 to 1971 and recovered when shot or found dead in 1966 to 1976 [29]. Therefore, the exact ages of these foxes were known. In foxes, the first cementum line develops between May and August of the fox's second year of life, after which a line develops annually in the autumn [11,12]. The cementum layers appear as characteristic rings consisting of paler opaque (summer) and darker transparent (winter) areas when using a stereo microscope [12].

To test the effect of the length of storage on ability to visualize dental lines with μ -CT, a tooth of one fox that had been killed in 2012 and prepared in 2015 (according to Roulichová et al., 2007 [20]) was analyzed. The tooth had been dried and stored at room temperature for three years before conducting the μ -CT. Between 2012 and 2015, the fox tooth was deep frozen. The age of this fox was estimated at 4 years using the traditional method [20].

Two mink (both at the age of two years) were sampled from Danish mink farms in 2018. In mink and other members of the family Mustelidae, cementum layers are difficult to discriminate via traditional methods. In many individuals assessed as adults, no incremental lines can be observed [2,30]. Therefore, Eurasian pine marten (*Martes martes*) and mink (and perhaps also for other mustelids), animals are aged by using a model describing the relationship between the pulp cavity width and the age of the individual [2,16].

The two harbor porpoises (named Frigg (harbor porpoise 1) and Sif (harbor porpoise 2)) were born or kept in captivity since they were juveniles at Fjord&Bælt, an aquarium and research institution in Denmark. Their ages were thereby known to be 5.5 and 13.5 years, respectively [31]. In harbor porpoises, GLGs develop on the inside of the neonatal line in the dentine crown that are visible as dark lines or "arcs" formed annually between January and September [12,17].

2.1. μ -CT of Foxes and Porpoises

The μ -CT of fox and porpoise teeth fixed on the sample holder in a floral sponge was obtained using a "Nikon XT H 225 ST" (Nikon Metrology Europe NV Leuven, Belgium) metrology device. The instrument was operated with a tungsten reflection target using 55 kV and 15 W. For image acquisition, 1571 projections with 1 s exposure time and a 2×2 binning were used, and 8 frames were averaged per projection. A total acquisition time of 4 h and 21 min was achieved per sample. Depending on the sample, the reconstructed isotropic voxel size was approximately 15 μ m (Table 1). The reconstruction of the tomographs was performed using the software "CT Pro 3D" (Nikon Metrology Europe NV Leuven, Belgium)) and included a correction for beam hardening effects.

2.2. μ -CT of Mink

The μ -CT of the mink teeth (all fixed on the sample holder with reusable adhesive gum), were obtained using a "ZEISS Xradia 410 Versa" (Carl Zeiss Microscopy, Oberkochen, Germany) device. The instrument was operated with a tungsten reflection target using 50 kV and 10 W, a ZEISS "low energy one" (LE1) filter, and a large field of view (LFOV) objective. A total of 1601 projections with 5 s exposure time per projection were recorded, and an isotropic voxel size of 15.8 μ m was obtained after a 2×2 binning. The full acquisition time was 3 h and 8 min in total. Image reconstruction was performed using the inbuilt acquisition and reconstruction software package (version 14.0.14829.38124) provided by ZEISS based on an algorithm using filtered back-projection [32].

2.3. Statistical Analysis

The true ages of the individuals of the three species (fox, mink, and harbor porpoise) were compared with counts of dentine layers of representative 2D slices of the 3D CT

images using a linear regression analysis (Pearson product–moment correlation test) and a Bland–Altman plot.

Table 1. Isotropic reconstructed voxel size used in the different measurements of foxes and harbor porpoises.

Journal Number	Isotropic Voxel Size/ μm
Fox 1 (838–839)	14.6
Fox 2 (948–949)	14.4
Fox 3 (1051–1052)	12.9
Fox 4 (3113–3114)	13.9
Fox 5 (3215–3216)	14.7
Fox 6 (894–895)	18.2
Fox 7 (689–690)	11.0
Fox 8 (707–708)	14.7
Fox 9 (3420–3421)	12.9
Fox 10 (741–742)	12.4
Fox 11 (4505–4506)	14.6
Fox 12 (705–706)	14.7
Fox 13 (693–694)	14.7
Harbor porpoise 1	6.4
Harbor porpoise 2	3.7
Fox R0182	14.5

3. Results

The teeth from 13 red foxes with known age, 2 mink, and 2 porpoises were all analyzed using $\mu\text{-CT}$.

There was a high agreement between dental layers visualized using CT and the real age of the individuals (Table 2; Appendix A Figures A1–A3); the number of layers and GLGs visible in the teeth were highly correlated with the exact ages of the foxes, mink, and harbor porpoises ($R^2 = 96\%$, $p < 0.001$), and the Bland–Altman plot indicated low variation and similar deviations when comparing the age of the individual and dental layers visible in the CT measurement (Figures 1 and 2). The average difference was -0.3 years; i.e., the true age was slightly higher than the estimated one, and the 95% confidence interval was -0.82 years to $+1.45$ years.

Table 2. Comparison of known age with the number layers visible in representative 2D slice of the 3D CT image.

Species No. and Journal No.	Age of Individual (Years)	Number of Dental Layers
Fox 1 (838–839)	4.9	4
Fox 2 (948–949)	1.5	2
Fox 3 (1051–1052)	1.7	1
Fox 4 (3113–3114)	1.7	1
Fox 5 (3215–3216)	1.9	2
Fox 6 (894–895)	6.4	6
Fox 7 (689–690)	4.6	5
Fox 8 (707–708)	2.8	2
Fox 9 (3420–3421)	2.2	3
Fox 10 (741–742)	6.8	7
Fox 11 (4505–4506)	4.3	3
Fox 12 (705–706)	1.6	2
Fox 13 (693–694)	3.8	3
Mink 1	2	2
Mink 2	2	1
Harbor porpoise 1	5.5	5
Harbor porpoise 2	13.5	14

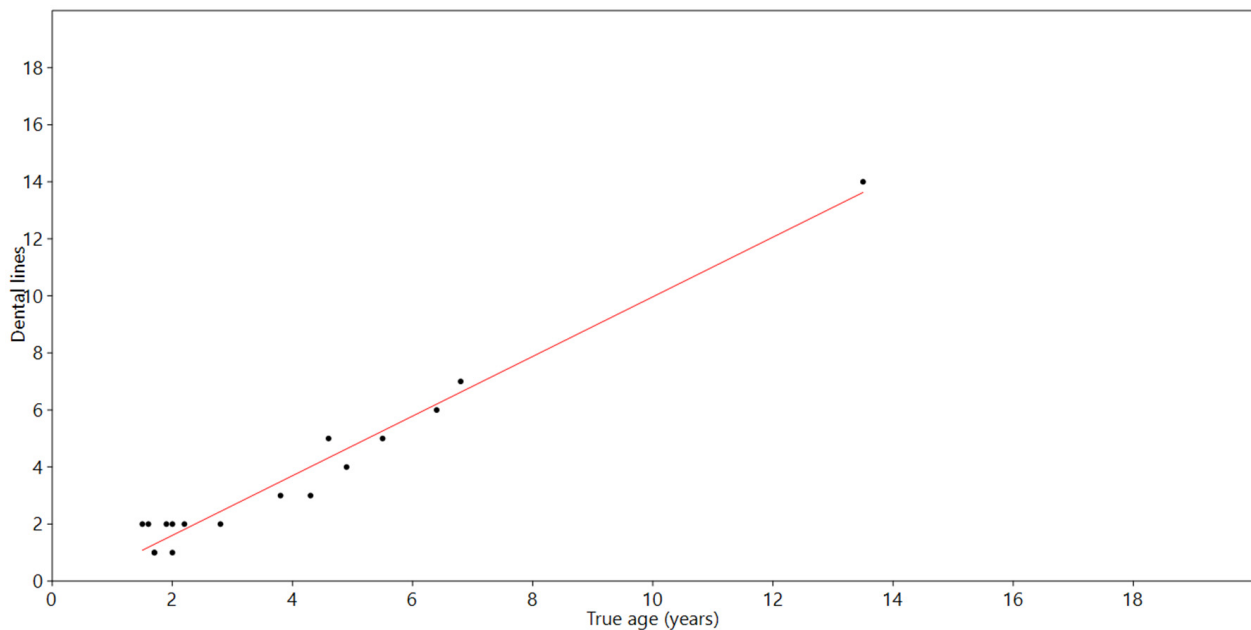


Figure 1. Linear regression between true age of all species and number of dental layers visible in CT-based measurements ($R^2 = 96\%$, $p < 0.001$).

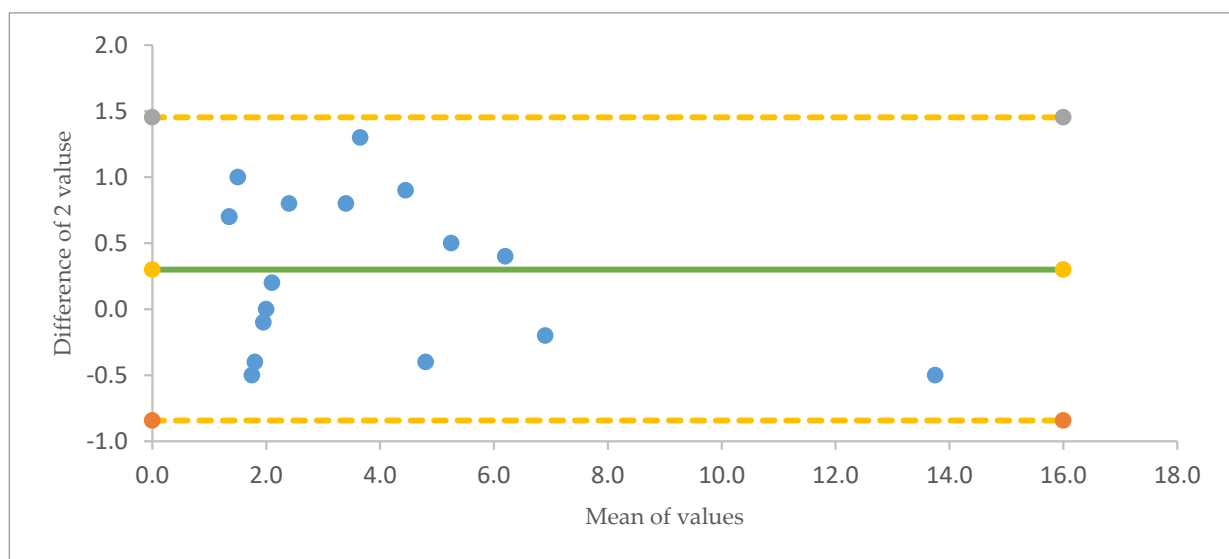


Figure 2. Bland–Altman Plot of true age (years) of individuals vs. the number of dental layers visible in a 2D slice of the 3D CT images. On average (green line), individuals were 0.3 years older than the number of lines visible. There was a 95% match in age between the real age and the age interpreted from dental layers. The number of lines visible were expected to fall in the range of -0.84 years (yellow line) and +1.45 years (yellow line) around the true age.

For the additional fox tooth that had been stored at room temperature for 3 years and was estimated to be 4 years old by conventional methods, four clearly visible dental layers were observed via μ -CT; these lines were much clearer than the lines in teeth of specimens stored dry and at room temperature for around nearly 50 years in a museum's collection (Figure 3). A movie showing fox R0182 in 3D, and during virtual slicing, can be found in the supplementary materials (S1).

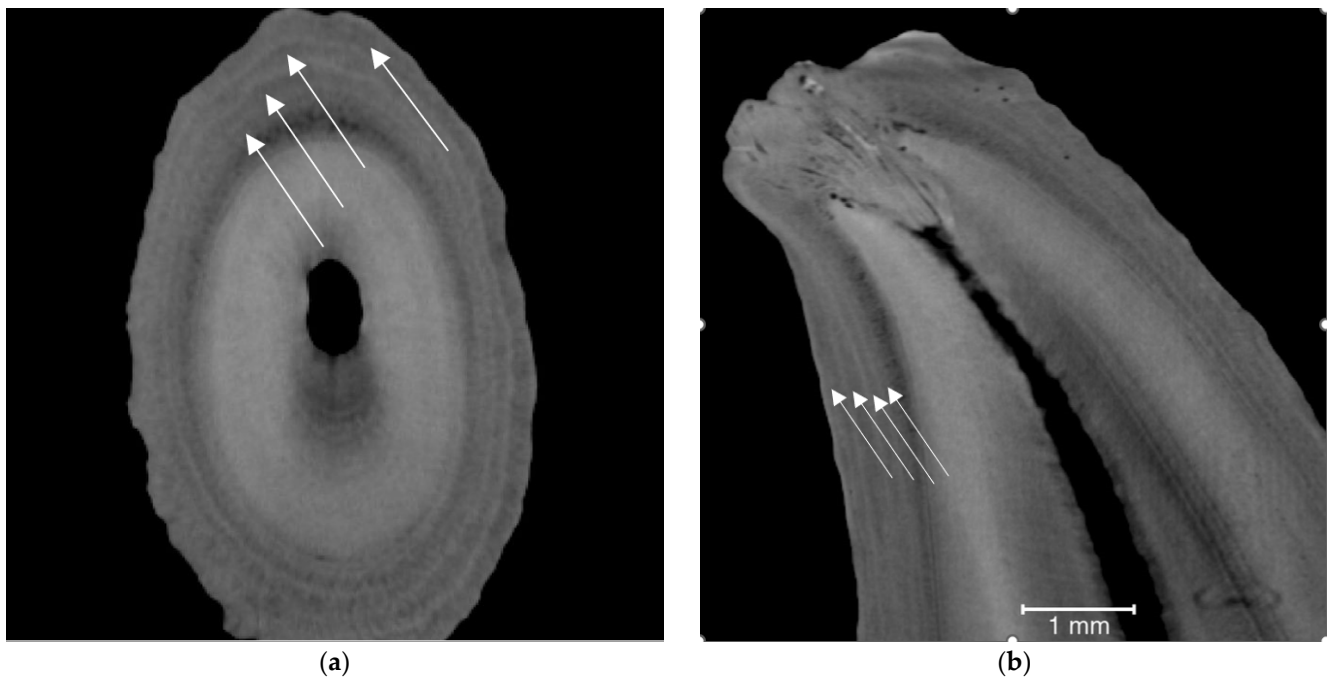


Figure 3. Two-dimensional images of fox tooth stored at room temperature for only 3 years before μ -CT: (a) transverse; (b) longitudinal. The fox was estimated to be 4 years old. Arrows point to dark layers.

4. Discussion

Despite minor variations in image quality, there was a high agreement between the known age and the number of dental lines visible in the dentine layer (Table 2; Figures 1 and 2; Appendix A Figures A1–A3). For a 95% confidence interval, one would expect a maximum difference between the interpretation by visible lines in the CT image and true age to be 1.5, whereas the biggest observed maximum was found to be 1.3 (see the Bland–Altman plot in Figure 2). In comparison, in a previous study of the age of Danish red foxes with known age and aged using the traditional method, the age estimation was correct in 93% (125 of 135) of the cases [12].

In carnivores, dental lines or layers are normally read outside the neonatal line, whereas in toothed whales the GLGs are read inside the neonatal line. However, in both carnivores and toothed whales, dental layers could be recognized on both sides of the neonatal line when examining the μ -CT images. For one mink, where two lines would be expected (Appendix A Figure A2 (Journal No. 15700_1)), only one line was visible on the outside of the neonatal line, while both lines were easily visible on the inside of the neonatal line. However, with careful examination, lines may be recognized on both sides of the neonatal line, but it was still our experience that it was easiest to read lines outside the neonatal line in the root of carnivores and in the dentine in toothed whales.

The different quality of CT images of dental layers—some had well-defined layers and some had blurred or faint layers—may have relied on different qualities of the cadavers before the skeletons are preserved as well as the health and growth patterns of the individuals. The time of storage may also have influenced the visibility of the dental lines in the foxes. Dental lines in a tooth from a fox stored for only 3 years were much clearer than those in teeth from foxes stored for around 50 years (Figure 3 vs. Appendix A Figures A1–A3). However, this assumption was based on a single sample, which does not allow us to draw strong conclusions; therefore, it is recommended to carry out further research in which the objective is to know the effect of storage with a larger sample size.

Previously, μ -CT studies using clinical scanners of sperm whale (*Physeter macrocephalus*) teeth have failed to visualize dental layers [26,27]. The present study showed that μ -CT was not only able to visualize growth layers in teeth of carnivores and toothed whales but

also could do so to an extent that they could be aged to a quality comparable to that of traditional methods.

5. Conclusions

To our knowledge, this was the first successful age determination of carnivores and toothed whales based on structurally non-invasive teeth X-ray CT.

The present study showed that μ -CT was not only able to visualize growth layers in the teeth of carnivores and toothed whales but also could do so to an extent that they could be aged to a quality comparable to that of traditional methods. The use of μ -CT does not imply the same destructive and time-consuming sample preparation, which is especially a benefit when imaging rare specimens for which preservation is required. If several teeth are imaged at the same time, the technique also outcompetes fast traditional preparation techniques. Furthermore, using μ -CT has a huge potential for extended information based on quantitative image analysis of the contrast differences in and between growth layers, which might provide information on feed availability and pregnancies in addition to (semi)-automized age determination.

Supplementary Materials: The following supporting information can be downloaded at: <https://www.mdpi.com/article/10.3390/ani13111783/s1>, Video S1: Movie showing fox R0182 in 3D and during virtual slicing. Some ring artefacts, arising from the image acquisition, appear as bright and dark spots or rings, dependent on the direction used for virtual slicing

Author Contributions: Conceptualization, M.C., M.S.H., S.B.-S., D.K.J., K.M.G. and S.P.; methodology, S.B.-S. and S.P.; software, S.B.-S. and C.G.; validation, A.K.O.A., L.B.H., M.W. and C.B.T.; formal analysis, S.P., A.K.O.A. and C.P.; investigation, S.B.-S. and S.P.; resources, S.B.-S. and S.P.; data curation, C.V.H., C.V.-S., S.P. and S.B.-S.; writing—original draft, S.B.-S. and S.P.; writing—review and editing, M.C., M.S.H., S.B.-S., D.K.J., C.G., K.M.G., C.P., C.V.-S., C.V.H., L.B.H., M.W., C.B.T., A.K.O.A. and S.P.; visualization, S.P.; project administration, S.B.-S. and S.P. All authors have read and agreed to the published version of the manuscript.

Funding: We acknowledge support from the Danish National Facility for Imaging with X-rays (DANFIX) funded by the Danish Agency for Science and Higher Education via grant ID 5072-00030B. S.B.S. is grateful for the financial support from Innovation Fund Denmark via grant 5152-00005B.

Institutional Review Board Statement: All applicable international, national, and institutional guidelines for the use of animals were followed. No ethical approval was needed from an institutional or national ethics review board. The study complied with current Danish laws.

Informed Consent Statement: Not applicable.

Data Availability Statement: The data presented in this study are available upon request from the corresponding author.

Acknowledgments: The National History Museum of Aarhus, Denmark, is thanked for loaning us fox skeletons from the museum's collection (Nos. 13,000 to 13,202).

Conflicts of Interest: The authors declare no conflict of interest.

Appendix A

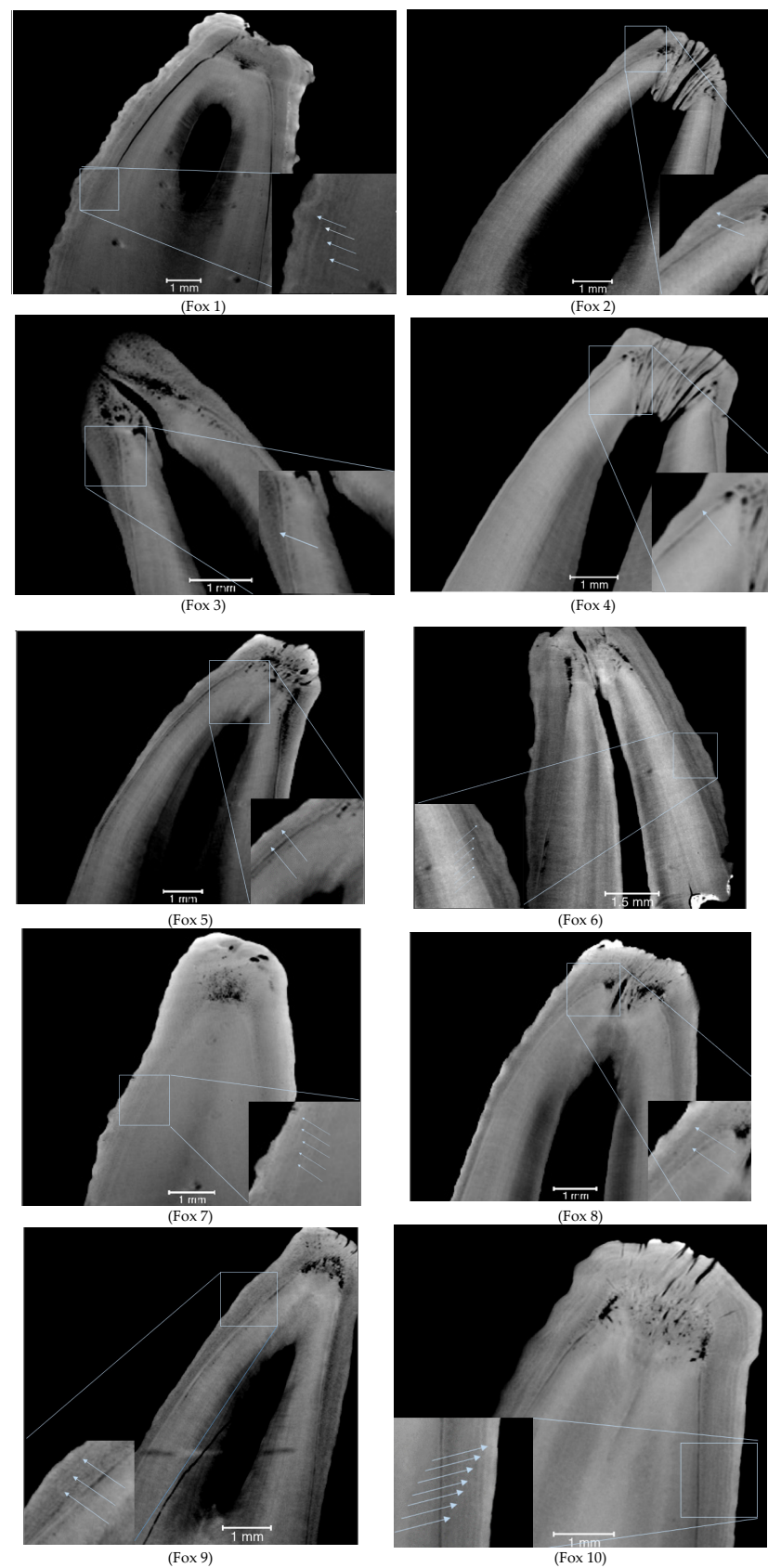


Figure A1. Cont.

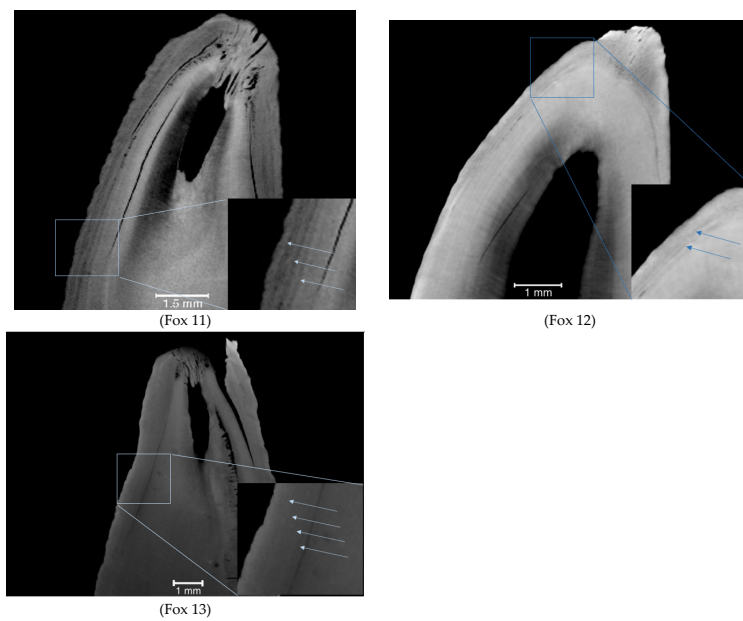


Figure A1. Fox 1–Fox 13. Visualizations of 2D slices of the 3D CT images of the 13 foxes in Table 2.

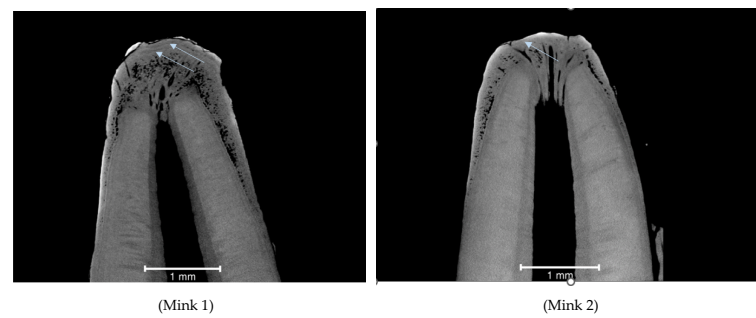


Figure A2. Mink 1 and Mink 2. Visualizations of 2D slices of the 3D CT image the two mink in Table 2.

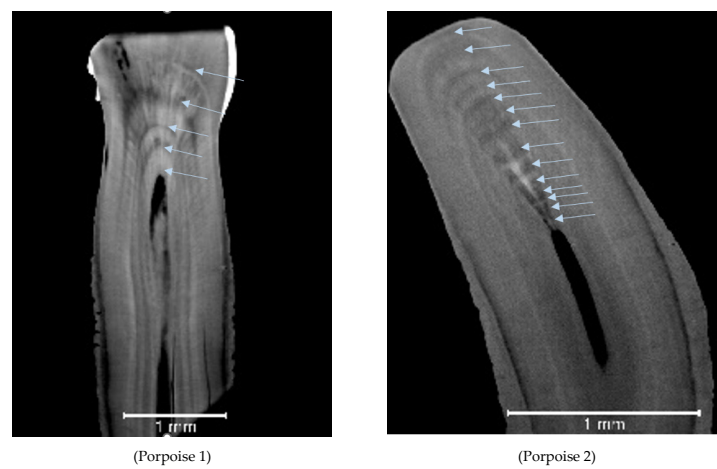


Figure A3. Porpoise 1 and Porpoise 2. Visualizations of 2D slices of the 3D CT image of the two porpoises in Table 2.

References

- Kesselring, T.; Viquerat, S.; Brehm, R.; Siebert, U. Coming of age: -Do female harbour porpoises (*Phocoena phocoena*) from the North Sea and Baltic Sea have sufficient time to reproduce in a human influenced environment? *PLoS ONE* **2017**, *12*, e0186951. [CrossRef] [PubMed]
- Pagh, S.; Pertoldi, C.; Chriél, M.; Petersen, H.H.; Jensen, T.H.; Madsen, S.; Kraft, D.C.E.; Schou, T.M.; Hansen, M.S. Estimation of the age and reproductive performance of wild-born and escaped mink (*Neovison vison*) caught in the wild in Denmark. *Animals* **2021**, *11*, 162. [CrossRef]
- Pagh, S.; Hansen, M.S.; Jensen, B.; Pertoldi, C.; Chriél, M. Variability in body mass and sexual dimorphism in Danish red foxes (*Vulpes vulpes*) in relation to population density. *Zool. Ecol.* **2018**, *28*, 1–9. [CrossRef]
- Pagh, S.; Chriél, M.; Madsen, A.B.; Jensen, T.W.; Elmeros, M.; Asferg, T.; Hansen, M.S. Increased reproductive output of Danish red fox females following an outbreak of canine distemper. *Canid Biol. Conserv.* **2018**, *21*, 12–20.
- Pagh, S.; Buxbom, J.; Chriél, M.; Pertoldi, C.; Pedersen, J.S.; Hansen, M.S. Modelled population growth based on reproduction differs from life tables based on age determination in Danish raccoon dogs (*Nyctereutes procyonoides*). *Mammal Res.* **2020**, *65*, 215–222. [CrossRef]
- Hohn, A.A.; Scott, M.D.; Wells, R.S.; Sweeney, J.C.; Irvine, A.B. Growth Layers in teeth from known-age, free-ranging Bottlenose dolphins. *Mar. Mammal Sci.* **1989**, *5*, 315–342. [CrossRef]
- Helle, E.; Kauhala, K. Age structure, mortality, and sex ratio of the raccoon dog in Finland. *J. Mammal.* **1993**, *74*, 936–942. [CrossRef]
- Jacobson, E.K.; Boyd, C.; McGuire, T.L.; Shelden, K.E.W.; Himes Boor, G.K.; Punt, A.E. Assessing cetacean populations using integrated population models: An example with Cook Inlet beluga whales. *Ecol. Appl.* **2020**, *30*, e02114. [CrossRef] [PubMed]
- Fontaine, M.C.; Roland, K.; Calves, I.; Austerlitz, F.; Palstra, F.P.; Tolley, K.A.; Ryan, S.; Ferreira, M.; Jauniaux, T.; Llavona, A.; et al. Postglacial climate changes and rise of three ecotypes of harbour porpoises, *Phocoena phocoena*, in western Palearctic waters. *Mol. Ecol.* **2014**, *23*, 3306–3321. [CrossRef]
- Betty, E.L.; Stockin, K.A.; Hinton, B.; Bollard, B.A.; Smith, A.N.H.; Orams, M.B.; Murphy, S. Age, growth, and sexual dimorphism of the Southern Hemisphere long-finned pilot whale (*Globicephala melas edwardii*). *J. Mammal.* **2022**, *103*, 560–575. [CrossRef]
- Grue, H.; Jensen, B. Annual structures in canine tooth cementum in red foxes (*Vulpes vulpes* L.) of known age. *Dan. Rev. Game Biol.* **1973**, *8*, 1–12.
- Grue, H.; Jensen, B. Review of the formation of incremental lines in tooth cementum of terrestrial mammals [age determination, game animal, variation, sex, reproductive cycle, climate, region, condition of the animal]. *Dan. Rev. Game Biol.* **1979**, *11*, 1–47.
- Frylestam, B.; Schantz, T. Age determination of European hares based on periosteal growth lines. *Mammal Rev.* **1977**, *7*, 151–154. [CrossRef]
- Frylestam, B. Growth and body weight of European hares in southern Sweden. *Ecography* **1980**, *3*, 81–86. [CrossRef]
- Kauhala, K.; Helle, E. Age determination of the raccoon dog in Finland. *Acta Theriol.* **1990**, *35*, 321–329. [CrossRef]
- Helldin, J.O. Age Determination of Eurasian Pine Martens by Radiographs of Teeth in Situ. *Wildl. Soc. Bull.* **1997**, *25*, 83–88.
- Lockyer, C. Application of a new method to investigate population structure in the harbour porpoise, *Phocoena phocoena*, with special reference to the North and Baltic Seas. *J. Cetacean Res. Manag.* **1999**, *1*, 297–304. Available online: <https://search.proquest.com/docview/17509162> (accessed on 30 October 2017). [CrossRef]
- Nielsen, N.H.; Garde, E.; Heide-Jørgensen, M.P.; Lockyer, C.H.; Ditlevsen, S.; Òlafsdóttir, D.; Hansen, S.H. Application of a novel method for age estimation of a baleen whale and a porpoise. *Mar. Mammal Sci.* **2013**, *29*, E1–E23. [CrossRef]
- Harris, S. Age determination in the Red fox (*Vulpes vulpes*)-an evaluation of technique efficiency as applied to a sample of suburban foxes. *J. Zool.* **1978**, *184*, 91–117. [CrossRef]
- Roulichová, J.; Andera, M. Simple method of age determination in red fox, *Vulpes vulpes*. *Folia Zool.* **2007**, *56*, 440. Available online: <https://search.proquest.com/docview/206328856> (accessed on 21 December 2007).
- Evans, K.; Himdell, M.A.; Lockyer, C.; Rice, D. Factors affecting the precision of age determination of sperm whales (*Physeter macrocephalus*). *J. Cetacean Res. Manag.* **2002**, *4*, 193–201. [CrossRef]
- Lockyer, C. A review of factors involved in zonation in odontocete teeth, and an investigation of the likely impact of environment factors and major life events on harbour porpoise tooth structure. In *Biology of Phocoenids*; Report of the International Whaling Commission, Special Issue 16; Bjørge, A., Donovan, G.P., Eds.; International Whaling Commission: Cambridge, UK, 1995; pp. 511–529.
- Luque, P.L.; Learmonth, J.A.; Santos, M.B.; Ieno, E.; Pierce, G.J. Comparison of two histological techniques for age determination in small cetaceans. *Mar. Mammal Sci.* **2009**, *25*, 902–919. [CrossRef]
- Pagh, S.; Chriél, M.H.A.; Nielsen, T.A.; Hansen, M.S. Age determination of sperm whales (*Physeter macrocephalus*) from the west coast of Jutland, Denmark. In Proceedings of the 13th Danish Marine Mammal Symposium, 2016; p. 1. Available online: <https://vbn.aau.dk/da/publications/age-determination-of-sperm-whales-physeter-macrocephalus-from-the> (accessed on 4 March 2016).
- Jasinski, S.E.; Abbas, S.G.; Mahmood, K.; Babar, M.A.; Khan, M.A. New Carnivoran (Mammalia: Carnivora) specimens from the Siwaliks of Pakistan and India and their faunal and evolutionary implications. *Hist. Biol.* **2022**. [CrossRef]
- Loch, C.; Schwass, D.R.; Kieser, J.A.; Fordyce, R.E. Use of micro-computed tomography for dental studies in modern and fossil odontocetes: Potential applications and limitations. *NAMMCO Sci. Publ.* **2013**, *8*. [CrossRef] [PubMed]

27. Alstrup, A.K.O.; Munk, O.L.; Jensen, T.H.; Jensen, L.F.; Hedayat, A.; Hansen, B. Magnetic resonance imaging and computed tomography as tools for the investigation of sperm whale (*Physeter macrocephalus*) teeth and eye. *Acta Vet. Scand.* **2017**, *59*, 38. [\[CrossRef\]](#)
28. Velasco, A.A.; Tanner, C.; Schulz, G.; Rodger, G.; Jackowski, J.; Humbel, M.; Weitkamp, T.; Bunn, H.T.; Müller, B. Hierarchical imaging of African bovid tooth cementum using X-ray microtomography. In Proceedings of the SPIE 12242, Developments in X-ray Tomography XIV 2022, 122420R, San Diego, CA, USA, 21–26 August 2022. [\[CrossRef\]](#)
29. Jensen, B. *Movements of the Red Fox “Vulpes vulpes L.” in Denmark, Investigated by Marking and Recovery*; Game Biology Station: Kalø, Denmark, 1973; pp. 11–21.
30. Whitman, J.S. Age structure differences in American Mink, *Mustela vison*, populations under varying harvest regimes. *Can. Field-Nat.* **2003**, *117*, 35–38.
31. Stepien, E.N.; Nabe-Nielsen, J.; Hansen, K.A.; Kristensen, J.H.; Blanchet, M.; Brando, S.; Desportes, G.; Lockyer, C.; Marcenaro, L.; Bunschoek, P.; et al. Determination of growth, mass, and body mass index of harbour porpoises (*Phocoena phocoena*): Implications for conservational status assessment of populations. *Glob. Ecol. Conserv.* **2023**, *42*, e02384. [\[CrossRef\]](#)
32. Feldkamp, L.A.; Davis, L.C.; Kress, J.W. Practical cone-beam algorithm. *J. Opt. Soc. Am. A Opt. Image Sci. Vis.* **1984**, *1*, 612. [\[CrossRef\]](#)

Disclaimer/Publisher’s Note: The statements, opinions and data contained in all publications are solely those of the individual author(s) and contributor(s) and not of MDPI and/or the editor(s). MDPI and/or the editor(s) disclaim responsibility for any injury to people or property resulting from any ideas, methods, instructions or products referred to in the content.