LTX-315 and adoptive cell therapy using tumor-infiltrating lymphocytes generate tumor specific T cells in patients with metastatic soft tissue sarcoma

Nielsen, Morten; Monberg, Tine; Sundvold, Vibeke; Albieri, Benedetta; Hovgaard, Dorrit; Petersen, Michael Mørk; Krarup-Hansen, Anders; Met, Özcan; Camilio, Ketil; Clancy, Trevor

Total number of authors:
15

Published in:
OncoImmunology

Link to article, DOI:
10.1080/2162402X.2023.2290900

Publication date:
2024

Document Version
Publisher's PDF, also known as Version of record

Taylor & Francis
Taylor & Francis Group

OncoImmunology

ISSN: (Print) (Online) Journal homepage: https://www.tandfonline.com/loi/koni20

LTX-315 and adoptive cell therapy using tumor-infiltrating lymphocytes generate tumor specific T cells in patients with metastatic soft tissue sarcoma

Morten Nielsen, Tine Monberg, Vibeke Sundvold, Benedetta Albieri, Dorrit Hovgaard, Michael Mørk Petersen, Anders Krarup-Hansen, Özcan Met, Ketil Camilio, Trevor Clancy, Richard Stratford, Baldur Sveinbjornsson, Øystein Rekdal, Niels Junker & Inge Marie Svane

To cite this article: Morten Nielsen, Tine Monberg, Vibeke Sundvold, Benedetta Albieri, Dorrit Hovgaard, Michael Mørk Petersen, Anders Krarup-Hansen, Özcan Met, Ketil Camilio, Trevor Clancy, Richard Stratford, Baldur Sveinbjornsson, Øystein Rekdal, Niels Junker & Inge Marie Svane (2024) LTX-315 and adoptive cell therapy using tumor-infiltrating lymphocytes generate tumor specific T cells in patients with metastatic soft tissue sarcoma, OncoImmunology, 13:1, 2290900, DOI: 10.1080/2162402X.2023.2290900

To link to this article: https://doi.org/10.1080/2162402X.2023.2290900

ONCOIMMUNOLOGY
2024, VOL. 13, NO. 1, 2290900
https://doi.org/10.1080/2162402X.2023.2290900

Taylor & Francis
Taylor & Francis Group

LTX-315 and adoptive cell therapy using tumor-infiltrating lymphocytes generate tumor specific T cells in patients with metastatic soft tissue sarcoma

Morten Nielsen[a], Tine Monberg[a], Vibeke Sundvold[b], Benedetta Albieri[a], Dorrit Hovgaard[c], Michael Mørk Petersen[c], Anders Krarup-Hansen[d], Özcan Met[a,e], Ketil Camilio[b], Trevor Clancy[f], Richard Stratford[f], Baldur Sveinbjornsson[b], Øystein Rekdal[b], Niels Junker[d], and Inge Marie Svane[a]

[a]National Center for Cancer Immune Therapy (CCIT-DK), Department of Oncology, Copenhagen University Hospital, Herlev, Denmark; [b]Lytix Biopharma, Oslo, Norway; [c]Department of Orthopedic Surgery, Copenhagen University Hospital Rigshospitalet, Copenhagen, Denmark; [d]Department of Oncology, Herlev and Gentofte Hospital, Herlev, Denmark; [e]Department of Health Technology, Technical University of Denmark, Lyngby, Denmark; [f]NEC Oncoimmunity AS, Oslo, Norway

ABSTRACT

LTX-315 is an oncolytic peptide that elicits both local and systemic immune responses upon intratumoral injection. In the present pilot trial, we treated patients with metastatic soft tissue sarcoma with the combination of LTX-315 and adoptive T-cell therapy using in vitro expanded tumor-infiltrating lymphocytes. Six heavily pretreated patients were included in the trial and treated with LTX-315 of which four patients proceeded to adoptive T-cell therapy. Overall, the treatment was considered safe with only expected and manageable toxicity. The best overall clinical response was stable disease for 208 days, and in this patient, we detected tumor-reactive T cells in the blood that lasted until disease progression. In three patients T-cell reactivity against in silico predicted neoantigens was demonstrated. Additionally, de novo T-cell clones were generated and expanded in the blood following LTX-315 injections. In conclusion, this pilot study provides proof that it is feasible to combine LTX-315 and adoptive T-cell therapy, and that this treatment can induce systemic immune responses that resulted in stabilization of the disease in sarcoma patients with otherwise progressive disease. Further optimization of the treatment protocol is warranted to increase clinical activity. ClinicalTrials.gov Identifier: NCT03725605

ARTICLE HISTORY
Received 15 September 2023
Revised 30 November 2023
Accepted 30 November 2023

KEYWORDS
Adoptive cell therapy; immunotherapy; LTX-315; soft tissue sarcoma; T-cell therapy; tumor infiltrating lymphocytes

Introduction

Soft tissue sarcomas (STSs) are a heterogeneous group of rare malignancies that arise from connective tissue. The prognosis for patients with advanced disease is poor and effective systemic treatments options are limited. Standard treatment for advanced STS is chemotherapy, but even with treatment the median overall survival is approximately 14–17 months.[1] Thus, improved treatment options are desperately needed.

Cancer immunotherapy, including immune checkpoint blockade and T-cell therapy, has advanced exponentially during the last decade, and proven to be successful across a range of different malignancies. Unfortunately, the percentage of STS patients that show benefit from immunotherapy is still rather low,[2,3] most probably due to high heterogeneity, immune quiescence, and immune suppression in the tumor microenvironment.[4]

Adoptive cell therapy (ACT) using tumor-infiltrating lymphocytes (TILs) is an advanced therapy medicinal product (ATMP) established by isolation of TILs from the patient's tumor. TILs are subsequently expanded in a GMP laboratory, and reinfused back into the patient. [5] TIL-based ACT has shown impressive clinical results in patients with metastatic melanoma (MM) with response rates around 40% to 50% including complete tumor regression and long-term survival in up to 20% of patients.[6,7] A recent phase 3 trial comparing ACT with ipilimumab for patients with MM reported significantly superior PFS in the ACT group.[8] TIL-based ACT for non-melanoma patients has yet to show convincing results. However, a limited number of small trials and case-reports have reported encouraging results from patients with cholangiocarcinoma,[9] breast cancer,[10] and cervical cancer.[11] In larger trials, however, clinical benefit is less frequent compared to melanoma.[12,13]

LTX-315 is an oncolytic 9-mer peptide of non-viral origin that is in clinical development for the treatment of solid tumors and is currently being evaluated in two separate Phase II clinical trials for skin cancer in the US (NCT04796194) and EU (NCT01986426). The peptide has demonstrated the ability to kill human cancer of diverse origin. [14] LTX-315 exerts its activity through a membranolytic effect and is equally active against both drug-resistant and drug-sensitive cancer cells.[14,15] Both preclinical and clinical studies have documented that intratumorally administered LTX-315 induces necrosis and significant T-cell infiltration into the tumor microenvironment.[16–20] In a recent Phase I/II study, significant expansion of the T-cell clone repertoire in blood was observed following LTX-315 treatment. Analysis of tumor tissue biopsies showed that 50% of the T-cell clones expanded in blood were

CONTACT Inge Marie Svane inge.marie.svane@regionh.dk National Center for Cancer Immune Therapy (CCIT-DK), Department of Oncology, Copenhagen University Hospital, Herlev Hospital Borgmester Ib Juuls Vej 13, Herlev DK-2730, Denmark
Supplemental data for this article can be accessed online at https://doi.org/10.1080/2162402X.2023.2290900

also identified in the tumor tissue following treatment, indicating that they were tumor-associated.[20]

In this pilot study, ATLAS-IT-04, we treated heavily pretreated patients with unresectable or metastatic STS with the combination of LTX-315 and ACT using *in vitro* expanded TILs. The objective was to evaluate the safety and potential for LTX-315 to induce TILs prior to isolation and expansion. Tumor-antigen specificity of expanded TILs and peripheral blood mononuclear cells (PBMCs) were assessed to reveal whether tumor specific T cells were generated *in vivo* following treatment.

Materials and methods

Patients

Eligible patients were between 18 and 75 years of age; had confirmed advanced or metastatic STS with stable disease or had progressed after a minimum of one line of systemic treatment for advanced/metastatic disease. All patients had one lesion accessible for injection that could be surgically removed, and at least one other target lesion that was measurable by CT (as per RECIST 1.1). All patients were required to have Eastern Cooperative Oncology Group (ECOG) performance status of 0 or 1, normal cardiac function, and baseline blood laboratory parameters indicating adequate bone marrow, kidney, and liver function. Patients with a history of systemic autoimmune disease requiring anti-inflammatory therapy or immunosuppressive therapy within the last three months prior to study drug administration, incomplete recovery from adverse events (AEs) due to prior therapies, and those with active or unstable metastases in the central nervous system were excluded from the study. A full overview of the eligibility criteria is provided in Supplementary Table S1. Patients evaluable for antitumor response by RECIST 1.1 received at least one injection of LTX-315, ACT and had at least one post dosing tumor evaluation.

Trial design

The trial was designed as a two-part interventional study with intratumoral injections of LTX-315 (step 1) followed by ACT and IL-2 treatment (step 2) (Figure 1). Six patients completed step 1. Primary objectives were to determine the safety of LTX-315 and ACT in combination, along with effectiveness of LTX-315 to induce T-cell infiltration in STS. Secondary objectives were to assess the anti-tumor effect of the LTX-315 and ACT in combination, and to assess the ability to expand CD8+ T cells *in vitro* from tumors pre-treated with LTX-315. Exploratory objectives were to assess tumor-antigen specificity of expanded TILs and PBMCs and to characterize the changes in the immune response following treatment. The study was conducted in accordance with the Helsinki Declaration[21] and approved by the National Committee on Health Research Ethics (H-18004924), the Danish Data Protection Agency, and the Danish Medicines Agency (2018014460). ClinicalTrials.gov Identifier: NCT03725605

Treatment

Patients with histologically confirmed metastatic STS and a tumor accessible for LTX-315 injections were eligible for inclusion. Patients were treated with 5 mg LTX-315 per injection for up to four weeks depending on clinical status. During the study, an amendment was made that allowed inclusion of patients that had SD as these patients are known to eventually progress rapidly. This SD condition, on the other hand, allow for a prolonged injection schedule. The number of injections per day depended on the size of the tumor (further details are provided Supplementary material 1). Within three weeks after the completion of LTX-315 treatment, the injected tumor was surgically removed for *in vitro* TIL expansion (Table 2).

ACT was preceded by one week of lymphodepleting chemotherapy with cyclophosphamide (60 mg/kg) at day −7 and −6, and fludarabine phosphate (25 mg/m^2) at day −5 to −1, as described in previous studies.[22] TILs were transferred as a single intravenous infusion on day 0 in Step 2. Following TIL infusion patients received subcutaneous IL-2 (2 MIU) for 14 days or until unacceptable toxicity.[23] All patients received prophylactic antibiotics, antiemetics and blood transfusions when clinically indicated.

Assessment of tumor response

Tumor response was assessed by RECIST 1.1.[24] Progression free survival (PFS) was calculated as the number of days from date of treatment start (baseline) until date of PD.

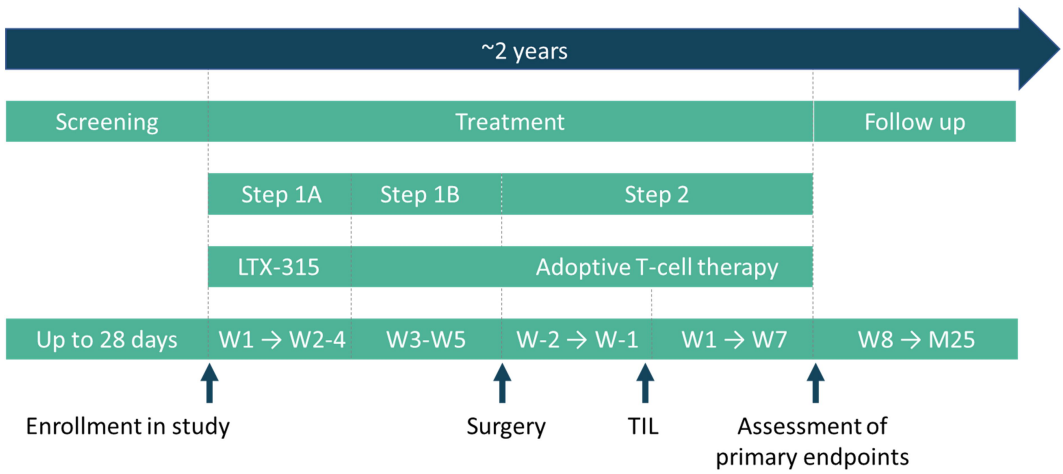

Figure 1. Study design.

TIL generation

The manufacturing procedure was performed in cleanrooms according to GMP EU Annex 1. TILs were expanded *in vitro* according to the "Young TIL" method.[25,26] Within hours from surgical removal of the tumor, the tumor specimen was cut into small fragments and placed in individual wells with culture medium containing RPMI 1640 (Thermo Fisher Scientific), 10% human serum (Sigma-Aldrich), IL-2 6000 IU/mL (Novartis), and Penicillin, Streptomycin and Fungizone (Thermo Fisher Scientific). During expansion, TIL cultures were pooled together to generate a bulk TIL product.

Following initial expansion, TILs were further expanded according to the Rapid Expansion Protocol (REP) for fourteen days.[27] The REP was initiated in static culture containers with 2×10^7 TILs in REP medium containing RPMI 1640/AIM-V (Thermo Fisher Scientific), 10% human serum, IL-2, anti-CD3-antibody (OKT3) (Miltenyi Biotec) and irradiated allogeneic feeder cells in a 1:200 ratio. Between day 6 and 9, depending on cell growth, the cell culture was transferred to a dynamic Xuri W25 bioreactor (Cytiva). On day 14, the cell culture was harvested, centrifuged, and washed.

Necrosis assessment and immunohistochemistry (IHC)

One to three core needle biopsies of the tumor were collected before the first treatment and at resection. The biopsies were embedded in paraffin, sectioned and stained with hematoxylin and eosin for quality assessment and evaluation of necrosis by a pathologist (Veracyte, France). Sectioned tissue biopsies were stained by IHC for CD3, CD4 and CD8. Staining was performed on slides using the Roche Ventana Benchmark XT autostainer. After antigen retrieval, staining was performed on consecutive slides using CD8 antibodies (clone C8/144B, Veracyte), CD3 antibodies (clone MRQ39, Veracyte), and CD4 antibodies (clone SP35, Roche) and detected with secondary antibody using the Ultraview Universal DAB detection kit. Image acquisition was performed using the Hamamatsu Nanozoomer XR scanner. The Veracyte Digital Pathology Platform was used for quantification of CD3, CD8 and CD4 density in the whole tumor area.

Sequencing and prediction of tumor specific T-cell neoantigens

Next generation sequencing (NGS) and T-cell epitope predictions were used to identify tumor specific T-cell antigens (neoantigens). DNA and RNA were extracted from tumor tissue and compared with data from matched normal tissue (PBMCs) by (Personalis Inc CA, USA). Using whole exome sequencing (WES) NGS data from the tumor, and matched WES data from the normal PBMCs in addition to RNAseq based transcriptome data from the tumor as input; expressed tumor specific mutations and the immunogenicity of their associated neoantigens was predicted using the NEC Immune Profiler (NIP) software from NEC OncoImmunity. HLA genotypes were determined from the WES data of normal genomic DNA using the HLA typing software from Personalis Inc and confirmed by the NIP software. Peptides corresponding to predicted tumor-epitopes were synthesized (JPT Peptide Technologies GmbH, Germany) (Supplementary Table S2) and used to assess TILs and PBMCs reactivity.

Flow cytometry

Flow cytometry was performed to assess the phenotype and tumor reactivity of *in vitro* expanded TILs and PBMCs on a NovoCyte Quanteon Flow Cytometer (Agilent Technologies). Cells were washed in PBS (Lonza) and stained with fluorochrome-conjugated antibodies (Supplementary Table S3). Antibodies were selected to identify TIL subsets such as αβ T cells, γδ T cells, and NK cells as well as different differentiation and exhaustion markers.

T-cell activation assay by IFNγ ELISPOT

Enzyme-linked immune absorbent spot (ELISPOT) assay was performed to assess TIL and PBMC reactivity against autologous tumor cell line (TCL) and selected neo-peptides using 96-well plates (Merck Millipore) coated with IFNγ capturing antibody (clone 1-D1K (Mabtech). TILs or PBMCs were co-cultured with autologous tumor cell lines or neo-peptides and incubated overnight at 37°C in 5% CO_2. The experiments were performed both with and without peptide pulsing. Following incubation, plates were washed, and biotinylated secondary antibody (clone 7-B6-1-Biotin, Mabtech) was added. Afterwards, plates were washed again, and Streptavidin-ALP (3010–10, Mabtech) was added. Finally, BCIP/NBT (3650–10, Mabtech) was added and catalyzed by the enzyme conjugate to form spots visualizing IFNγ release of a cell at that location. Spots were counted using an Immunospot 2.0 Analyzer (Cellular Technologies Limited).

TCR sequencing

T-cell receptor (TCR) beta chain CDR3 regions of biopsies and PBMCs were sequenced by ImmunoSeq (Adaptive Biotechnologies), with primers annealing to V and J segments, resulting in amplification of rearranged VDJ segments from each cell. Clonality values were obtained through the ImmunoSeq Analyzer software (www.adaptivebiotech.com/immunoseq/analyzer). Differential abundance analysis was assessed to identify clones that were significantly expanded or contracted from baseline to post-treatment timepoints. Significantly expanded clones were identified in peripheral blood and then compared with those in pre-treatment and post-treatment tumor samples to determine expansion of tumor-associated T-cell clones.

Results

Patient demographics

Six patients with metastatic STS were included in the trial between January 2019 and March 2021. Five patients had progressive disease (PD) and one patient (01–1005) had stable disease (SD) at the time of inclusion. Baseline characteristics are shown in Table 1. The patients age ranged between 27 and 69 years, and they had received a minimum of one previous line of standard chemotherapy.

Table 1. Baseline patient demographics.

ID	Age	Sex	Histology	Sites of disease	Prior systemic treatment	Status at inclusion	ECOG PS
01–1001	27	F	Desmoplastic small round cell tumor	Breast, lymph nodes, pleura, liver	Epirubicin/cyclophosphamide; atezolizumab, vincristine/ifosfamide/doxorubicin/etoposide; vincristine/actinomycin D/ifosfamide	PD	0
01–1002*	-		-	-	-	-	
01–1003	40	F	Leiomyosarcoma	Muscle, bone, lung	Doxorubicin/olaratumab; olaratumab	PD	0
01–1004	35	M	Desmoplastic small round cell tumor	Subcutis, lymph nodes	Doxorubicin/cisplatin/etoposide; doxorubicin/vincristine/actinomycin D/etoposide/ifosfamide/cyclophosphamide; pazopanib	PD	1
01–1005	69	M	Solitary fibrous tumor	Abdomen	Doxorubicin/dexrazoxane	SD	1
01–1006	51	M	Sclerosing epithelial fibrosarcoma	Eye, bone	VIDE; VAI; gemcitabine/docetaxel; gemcitabine/paclitaxel; gemcitabine	PD	1
01–1007	49	M	Solitary fibrous tumor	Parotid gland, lung, liver, kidney	Doxorubicin/dexrazoxane	PD	0

*Screening failure.

Table 2. Treatment data.

ID	Metastasis site	LTX-315 no. of injections per day	LTX-315 total dose (mg)	LTX-315 to surgery (days)	Surgery to ACT (days)	Time hospitalized (days)	Infused cells (10e9)	CD3 (%)	CD4%	CD8 (%)	CD8+ total (10e6)
01–1001	Breast	3 + 3 + 3 + 3	60	15	49	20	48,8	99	96	1	210
01–1003	Lower back	4 + 4 + 4 + 4	80	17	41	20	62,8	99	78	13	7913
01–1004	Chest	2 + 2 + 2 + 2	40	22	-	-	-	-	-	-	
01–1005	Abdomen	2 + 2 + 2 + 2 + 2	50	35	49	24	51,6	99	86	2	826
01–1006	Thigh	8 + 8 + 4 + 4	120	21	-	-	-	-	-	-	
01–1007	Parotid gland	2 + 2 + 1 + 0	25	22	41	20	44,4	99	44	52	23177

LTX-315 administration

LTX-315 was injected intratumorally on three to five dosing days to one lesion per patient (Table 2). All six patients received treatment with LTX-315. The dose per injection was 5 mg, and the total dose administered varied from 25 to 120 mg. Patients received up to eight injections per treatment day dependent upon the lesion size. The median time from the first LTX-315 injection to surgery was 21 days (15–35). One patient (01–1005) received LTX-315 according to a prolonged schedule because of SD at inclusion. For two patients (01–1006 and 01–1007), the LTX-315 dose was reduced during treatment due to radiological signs of necrosis of the injected tumor. The decision to reduce the dose was made to minimize necrosis that would decrease the chance of successful TIL expansion. Four patients received ACT; the reason why two patients did not receive ACT was due to unsuccessful expansion of TILs. Mean time from first LTX-315 injection to TIL infusion was 67 days (58–84).

LTX-315 influences the tumor micro-environment

All six patients had paired pre- and post LTX-315 treatment samples collected from injected lesions. Although biopsies were aimed to be collected in viable tumor tissue close to, but not at the injection site, one sample (01–1005) was completely necrotic following LTX-315 treatment and therefore not available for analysis of TILs. In one patient (01–1005), samples from a bystander (non-injected) lesion were available before and after LTX-315. Three tumors had increased necrosis following LTX-315 treatment (Figure 2a), ranging from 35% to 100%. Tumors with no sign of necrosis by this assessment were desmoplastic small round cell tumor (DSRCT) (patient 01–1001 and 01–1004) and solitary fibrous sarcoma (patient 01–1007).

Changes in infiltration of CD3+, CD4+, and CD8+ T cells from baseline to time of resection in the whole tumor following LTX-315 treatment were determined by IHC. At baseline, all patients except 01–1003 had low infiltration of CD3+cells (<170 cells/mm^2 tumor tissue) and CD8+ cells (<140 cells/mm^{2}tumor tissue). A higher number of CD4+ cells than CD3+ cells were present at baseline for several patients, suggesting that the CD4+ cells are not restricted CD3+CD4+ T cells.

CD3+ infiltration increased in three samples following LTX-315 treatment (patient 01–1001, 01–1006 and 01–1007) and decreased in two samples (patient 01–1003 and 01–1004) (Figure 2b). CD4+ infiltration increased after LTX-315 treatment in all samples that had increased CD3+ TILs and in patient 01–1003 (Figure 2c). CD8+ infiltration increased in two samples (patient 01–1001, 01–1007), decreased in two samples, and was unchanged in one sample (Figure 2d). Samples from the one available bystander lesion showed increased CD3+ and CD8+ infiltration but decreased CD4+ infiltration (Figure 2e).

TIL characteristics

Young TILs were successfully expanded from four out of six patients (Table 2). Mean expansion time from surgery to infusion was 45 days (41–49). Expansion during the REP ranged from 2220 to 3140-fold, with almost exclusively (>99%) CD3+ cells. Cells were a mix of CD4+ and CD8+ with CD4+ being predominant in three out of four cases. The mean number of infused cells was 51,9 $\times 10^9$ (44,4 $\times 10^9$ – 62,8 $\times 10^9$.

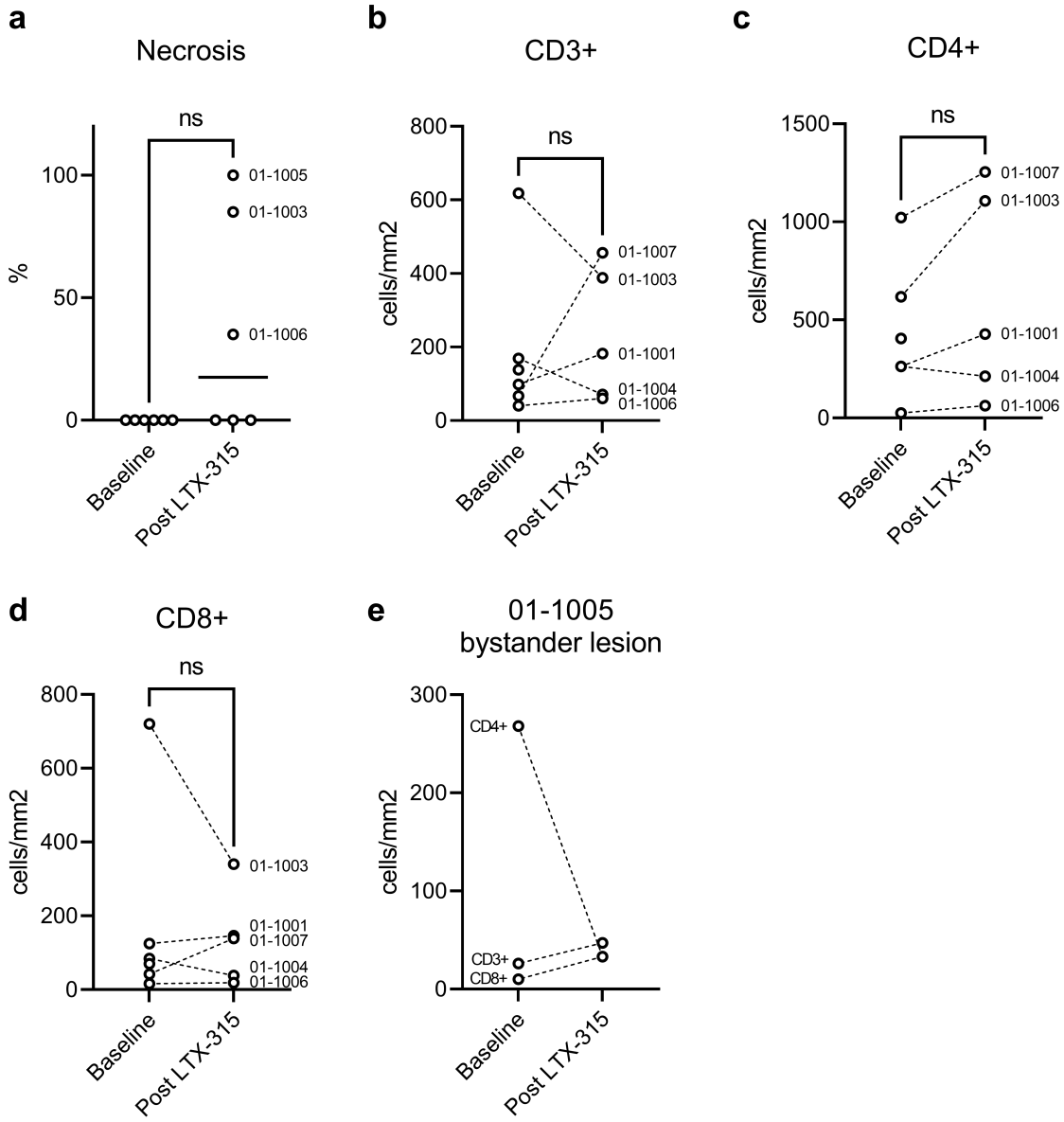

Figure 2. IHC data before and after LTX-315 treatment. Dot plot showing IHC data from tumor at baseline and after LTX-315 injections. (A) Necrosis are shown in percentage necrosis in the available tumor sample. Increased necrosis was noticed in three of six samples following LTX-315. (b-d) CD3+, CD4+ and CD8+ infiltration in the injected tumor as measured by IHC. (e) CD3+, CD4+, and CD8+ infiltration in a bystander lesion (non-injected tumor) at baseline and 19 weeks post LTX-315 treatment. T-cell infiltration is shown as cells/mm^2.

Safety

Treatment with LTX-315 was performed in an outpatient setting and was well tolerated with only grade 1 and 2 AE's (Table 3). Patients were hospitalized for 20 to 24 days during ACT treatment. All four patients that received ACT experienced grade 4 neutropenia and thrombocytopenia following lymphodepleting chemotherapy. The most common grade 3 AE was fever related to TIL infusion and IL-2 treatment. One patient (01–1005) only received two out of 14 planned IL-2 injections due to hypoglycemia and poor general condition following ACT.

Clinical efficacy

Four patients completed the treatment and were evaluable for objective response. Three out of four patients had SD six weeks after ACT (Figure 3) as best overall response (BOR). Progression free survival (PFS) was calculated as the number of days from the date of screening (baseline) until the date of PD. The PFS ranged from 72 days for patient 01–1007 to 208 days for patient 011003. For patient 01–1001 and patient 01–1005 PFS was 162 days and 170 days, respectively. All patients eventually had PD. Mean progression free survival was 22 weeks (10–30) from baseline.

In vitro anti-tumor reactivity of TILs and PBMCs as measured by ELISPOT

Anti-tumor reactivity of the PBMCs and TILs (infusion product) were tested against an autologous tumor cell line (TCL) in an IFNγ ELISPOT assay (Supplementary figure S1). We observed PBMC reactivity against autologous TCL in three

Table 3. Adverse events related to therapy.

Therapy	AE	Grade 1–2 (n)	Grade 3–4 (n)
LTX-315	Diarrhea	1	0
	Fever	1	0
	Itching	1	0
	Pain at injection site	4	0
	Redness at injections site	1	0
	Stomach pain	1	0
Chemotherapy	Anemia	3	0
	Constipation	1	0
	Diarrhea	1	0
	Dry mouth	1	0
	Fatigue	***1***	***1***
	Headache	1	0
	Hematuria	1	0
	Hot flashes	1	0
	Hypocalcemia	1	0
	Hypomagnesaemia	1	0
	Hyponatremia	1	0
	Hypophosphatemia	1	0
	Nausea	4	0
	Neutropenia	***0***	***4***
	Rash	2	0
	stomach-ache	1	0
	Stomatitis	1	0
	Thrombocytopenia	***0***	***4***
	Vomiting	1	0
TIL	Chills	2	0
	Diarrhea	1	0
	Dyspnea	***0***	***1***
	Fatigue	***0***	***1***
	Fever	***2***	***2***
	Headache	1	0
	Rash	1	0
IL2	Anemia	2	0
	Diarrhea	3	0
	Elevated alkaline phosphate	1	0
	Elevated liver enzymes	1	0
	Fever	***2***	***2***
	Headache	1	0
	Rash	1	0
	Vomiting	1	0

Grade 3–4 events are highlighted in **bold**/*italic*.

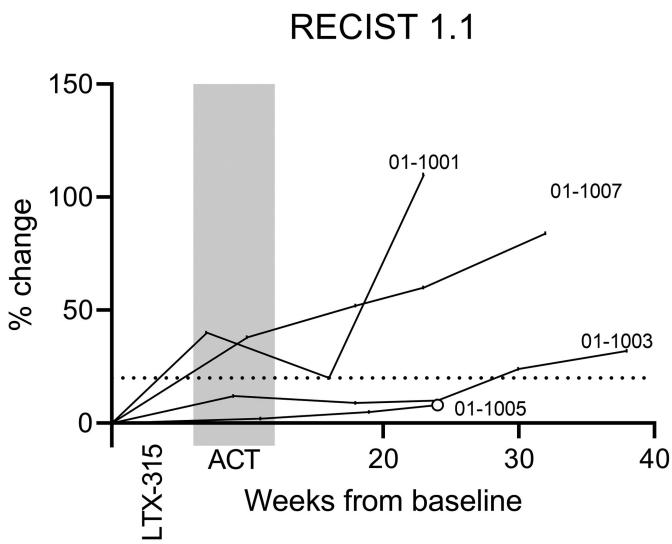

Figure 3. Tumor response assessed by RECIST1.1. Clinical effect of the treatment measured by RECIST 1.1. On the vertical axis are changes in the sum of target lesions and on the horizontal axis are time from baseline. A white circle at the end of a line refers to clinical PD determined by the treating physician.

patients. In patient 01–1003, reactivity appeared following treatment and increased over time until the time of progression, suggesting an induced *in situ* tumor response. Patient 01–1007 showed a similar profile with induced tumor reactivity after treatment, which also increased over time. The latter patient also showed TIL reactivity against TCL. Patient 01–1001 had tumor reactive PBMCs already at baseline which increased at assessment 6 weeks after ACT but disappeared when the patient had progressed 12 weeks after ACT. TIL reactivity was also assessed by flow cytometry with reactivity defined as expression or production of at least two predefined markers (CD137, CD107a, IFNγ, and TNFα) upon stimulation with autologous tumor digest. We observed reactivity in one (01–1001) of four tested samples, with the most frequent functional change in the TIL being expression of CD137 and CD107a (Figure 4b,c).

Neoantigens were predicted *in silico* for three patients and a selection of these neoantigens (Supplementary Table S2) were tested for reactivity with the patients PBMC and TIL product (Figure 4 and Supplementary Figure S1).

In patient 01–1001, a weak response was present in PBMC collected at baseline for only one neopeptide (neopeptide 1). LTX-315 treatment induced a response against 4 out of 7 neo-peptides, with the response against three of these neopeptides peaking at 6 weeks after ACT, and disappearing at 12 weeks after ACT when the patient had PD. For patient 01–1003 and 01–1007, we observed PBMC reactivity against > 50% of the tested neopeptides at baseline, but this reactivity was reduced following treatment. No TIL reactivity was observed against any of the predicted neopeptides.

Increased T-cell repertoire in PBMC induced by LTX-315

Changes in T-cell clonality were assessed in two patients (01–1003 and 01–1007). The frequency of each T-cell clone was examined in pre- and post treatment blood and tissue samples, as well as in the infused TILs. To identify those T-cell clones whose frequencies differed between pre-treated and post-treated samples, an algorithm described by DeWitt and colleagues was used.[28] T-cell clones with significant clonal expansion were identified and counted (Figure 5). In healthy individuals, an average of 13 T-cell clones have been reported as significantly expanding in a 2-week interval.[29] The number of significantly expanded T-cell clones after LTX-315 treatment was 91 clones for patient 01–1003 and 35 clones for patient 01–1007, both above the mean number found in healthy individuals, indicating that LTX-315 induced a systemic immune response in these two patients. Novel T-cell clones were detected in both patients after LTX-315 treatment. They expanded significantly in the periphery (Figure 5, highlighted in the box on y-axis).

Discussion

TIL based ACT has consistently shown impressive clinical results in patients with MM, but for non-melanoma cancer patients, clinical responses are less frequent. We assessed whether pre-treatment with intratumoral injections of LTX-

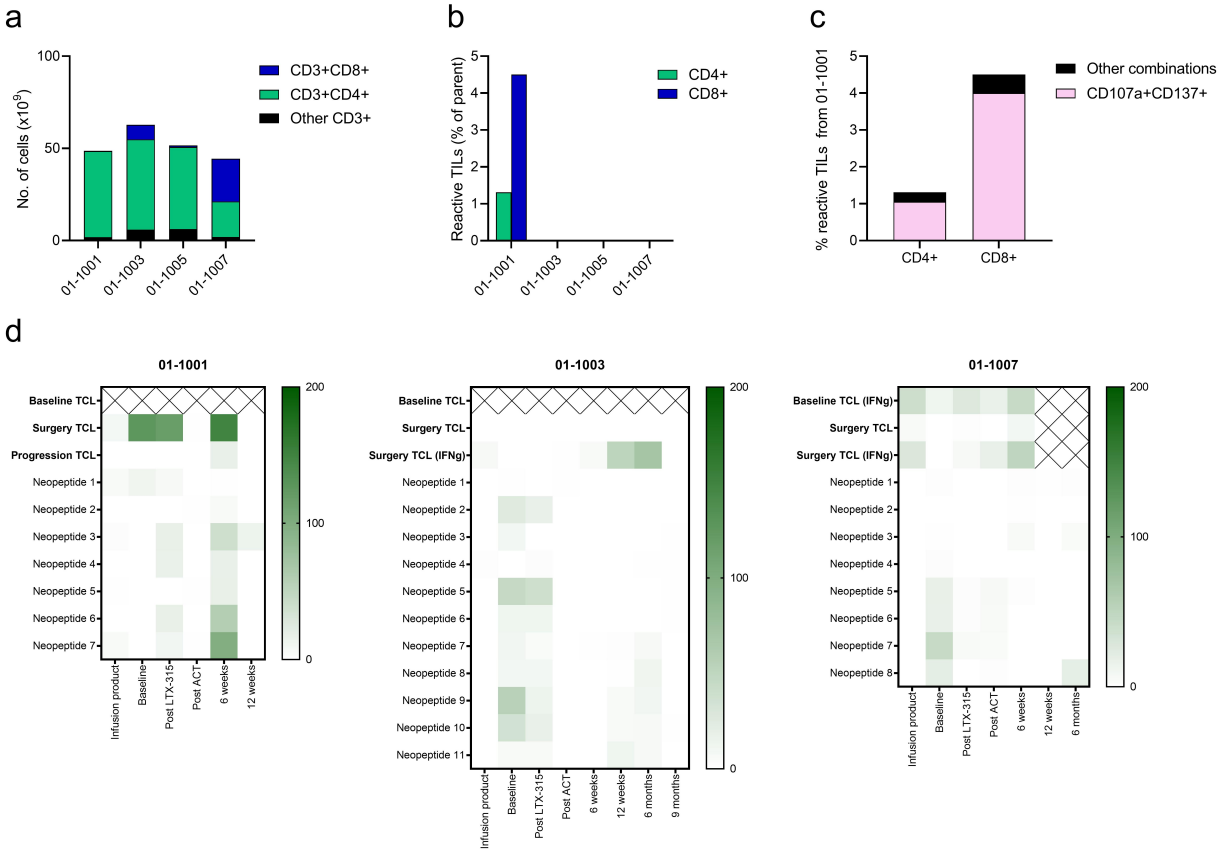

Figure 4. Characteristics and reactivity of TIL and PBMC. (a) Stacked bar plot showing phenotype of infused cells. (b) Bar plot showing percentage of tumor-reactivity in infused cells assessed by flow cytometry. (c) Stacked bar plot showing functional changes in reactive TILs when co-cultured with autologous tumor fresh tumor digest. (d) Heatmaps showing reactivity of PBMC, and infused TIL analyzed with IFNγ ELISPOT. Data are shown for the individual patients with target cells/peptides on the vertical axis and TIL/PBMC (chronologically) on the horizontal axis. Color intensity shows the difference between spot count of the test samples (mean of triplicates) and the negative control.

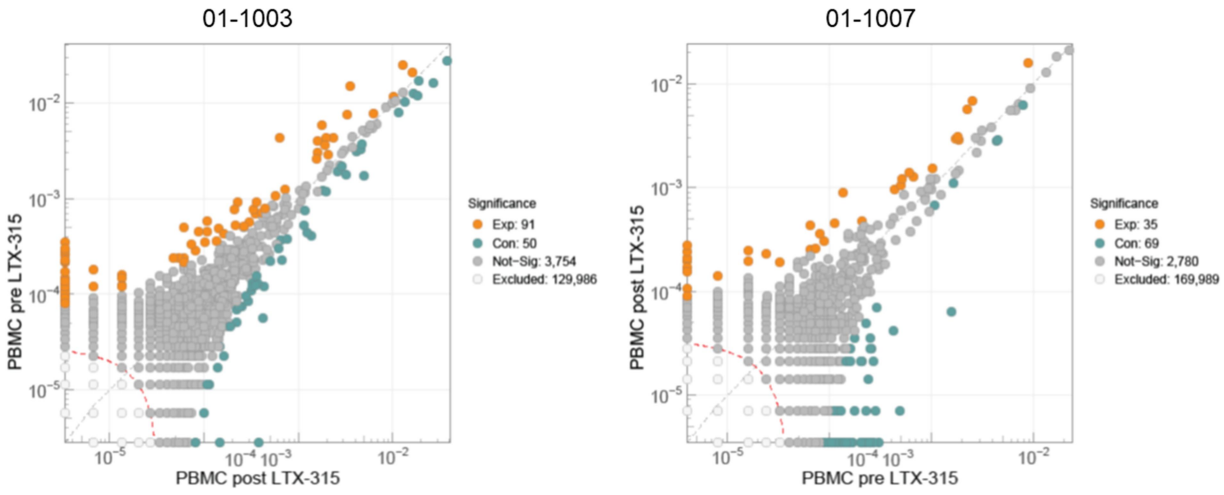

Figure 5. LTX-315 induces a polyclonal tumor-associated T-cell response in PBMC. Graph showing the abundance of unique T-cell clones in blood (peripheral blood mononuclear cells) before treatment compared with 17-22 days after initiation of LTX-315 treatment. T-cell clones that were not significantly changed in frequency are depicted in gray, whereas those that were significantly expanding, or contracting are depicted in red or blue, respectively. Dashed diagonal gray line defines frequency equality, and dashed red line defines threshold for statistical comparison.

315 could induce a tumor-specific immune response and increase T-cell infiltration, thus improving the quality of the *in vitro* expanded cells used for ACT. The primary objectives of the study were to assess the LTX-315 induced T-cell infiltration in treated tumors, and to assess the safety of the combination treatment.

The results from this clinical trial demonstrate that the combination of LTX-315 and ACT is safe and feasible with

expected and manageable toxicity. In this hard-to-treat patient population, no objective responses were achieved; BOR was SD in three out of four patients. The median PFS was 22 weeks, and the longest duration of disease stabilization was achieved in a patient with leiomyosarcoma (01–1003) who had SD for 208 days from screening (26 weeks from first LTX-315 injection and 17 weeks from ACT). Interestingly, immune mediated clinical benefit was demonstrated in a previous trial in a leiomyosarcoma patient treated with LTX-315.[20]

Importantly, this trial demonstrates that TILs can be successfully expanded *in vitro* to clinically meaningful numbers from LTX-315 pretreated tumors. The success rate of TIL expansion was 67% (four out of six patients), which is lower than previously reported.[30] This could be due to low baseline TIL infiltration, necrosis, or variation because of the small sample size. The rarity of sarcomas and the complex study treatment posed a significant challenge in the inclusion process. Patients will have to be in a physical condition to not only endure a potentially toxic treatment, but also be expected to maintain this physical condition while waiting for manufacturing of TILs for ACT. In a pre-clinical study performed at our institution we observed faster expansion of TILs from undifferentiated pleomorphic sarcoma (UPS) and myxofibrosarcomas than other sarcomas.[30] Clinical studies also suggest that patients with UPS and alveolar soft part sarcoma may respond to treatment with immune checkpoint inhibitors (ICIs).[31,32] These subtypes were not among the included diagnoses in this trial.

Combining immunotherapy with local treatment has previously shown promising results by enhancing the systemic effect of the treatment. LTX-315 induces immunogenic cell death and hereby exposes the immune system to tumor antigens as well as endogenous danger signals.[15] LTX-315 exerts its activity through membranolytic effects and has demonstrated the ability to kill cancer cells of diverse origin. The specificity for tumor cell killing results from cationic amino acids within the LTX-315 peptide chain interacting with the abundant anionic phospholipids present at higher levels in tumor cells compared with normal cells.[33,34] Through its membranolytic mode of action, LTX-315 induces immunogenic cell death locally in all cancer cells independent of resistant phenotype and can expose a broad repertoire of danger signals and tumor specific antigens with subsequent generation of a systemic immune response. Taking the advantage of the whole antigen repertoire of each patient´s tumor, the intratumoral treatment with LTX-315 represents an *in situ* vaccination principle where an immune response to tumor antigens (including the tumor specific neoantigens) in a patient-specific manner is generated *in vivo* without the need of the labor-intensive, costly and time-consuming manufacture of a personalized patient-specific vaccine. In this study, we successfully identified potential neoantigens from tumor cells that were recognized by T cells in the peripheral blood. In total, 26 predicted neoantigens were tested, and responses were observed with 17 (65%) of these, of which the response to 5 neoantigens were induced by LTX-315 (patient 01–1001) (Figure 4). The selection of potential neoantigens from somatic cancer mutations based on machine learning algorithms does not necessarily represent all specific tumor antigens in the patient's tumor. As seen in Figure 4, opposite to patient 01–1001, T cells from patients 01–1003 and 01–1007 respond to TCL but not to the neoantigens tested. This can be explained by the fact that TCL may comprise a broader repertoire of tumor specific antigens above and beyond neoantigens derived from somatic cancer mutations.

In two patients (01–1003 and 01–1007), we observed tumor-reactive T cells in the periphery blood at baseline, but this signal disappeared following treatment. It is possible that the preparative chemotherapy regimen is the cause of this although the clinical implication is unknown. Lymphodepleting chemotherapy prior to ACT is associated with increased clinical outcome in melanoma patients, however, the underlying mechanism is complex and not fully understood.[22] Among possible explanations are that lymphodepletion decreases the number of regulatory T cells and increases the levels homeostatic cytokines that promote T cell proliferation and survival.[35,36] Consensus remains that preparative chemotherapy increases the clinical effect of ACT. However, it is possible that this the lymphodepletion could affect an already existing antitumor immune response induced by LTX-315 treatment.

Paired biopsies from non-injected lesion were available from only patient 01–1005 and revealed a marginal increase in CD3+ and CD8+ T cells after treatment. Systemic immune responses induced by LTX-315 were more persuasive by assessment of the TCR repertoire in the blood. Blood samples from both patients that were assessed (01–1003 and 01–1007) demonstrated that treatment with LTX-315 induced significant expansion of a higher number of T-cell clones in the periphery than found in healthy individuals. Interestingly, *de novo* T-cell clones were generated and a proportion of these expanded significantly after LTX-315 treatment (Figure 5). Novel T cell reactivity against tumor antigens was demonstrated by ELISPOT assessment showing induced T-cell activity against neo-peptides (patient 01–1001) and TCL (patient 01–1003 and 01–1007), demonstrating that LTX-315 treatment indeed induces tumor specific T-cell responses that remain in the patients for at least 6 weeks after ACT. These data are aligned with previous data from Phase I/II trials where LTX-315 treatment increased the number of significantly expanded T-cell clones in patient blood with evidence of abscopal effect in non-injected lesions.[19,20]

LTX-315 treatment can induce necrosis within the tumor microenvironment followed by increased T-cell infiltration. Necrosis poses a challenge because vital tumor tissue is needed for *in vitro* TIL expansion. In other study designs, e.g., LTX-315 in combination with checkpoint-inhibitors, this is not considered an issue because necrosis may be beneficial for the induced immune response.

In this trial, we observed increased necrosis in the injected lesions following treatment in three out of six patients in tissue samples evaluated by a pathologist (Figure 2a). Moreover, significant necrosis was observed by radiological assessment during the treatment period in Step 1 in patient 01–1006 and 01–1007, resulting in reduced LTX-315 dosing to not necrotize the entire lesions. These unscheduled dose reductions

highlights a need to determine the number of injections with LTX-315 carefully and potentially include a more flexible injection schedule. Patient 01–1005 who was the only patient to receive LTX-315 according to the prolonged schedule had significant necrosis in the post-treatment biopsy but it was still possible to expand TILs for ACT from a non-necrotic part of the tumor. Although it is difficult to draw conclusions from a single case, this shows that a prolonged injection schedule does not exclude latter TIL expansion. Interestingly, the tumor from patient 01–1007 had significant necrosis by radiological assessment but revealed no necrosis when evaluated by pathologist. On the other hand, the post-treatment sample from patient 01–1005 were completely necrotic when assessed by pathologist, but we were still able to expand TIL for the treatment. These observations support the notion that needle biopsies does not represent the actual heterogeneity present in tumors and should be interpreted carefully. Aggregated necrosis assessment either by pathologist or radiology showed no signs of necrosis in the lesions in patients 01–1001 and 01–1004. To this end, we were not able to make any hypotheses or draw any correlation of the number of LTX-315 doses and necrosis, since their total dose exceeded the lowest dose at 25 mg LTX-315 (patient 01–1007). However, the indication may be decisive, as both patients 01–1001 and 01–1004 had DSCRT, including fibrotic tissue and hence lower abundance of tumor cells than in the other STS subtypes included herein. According to the LTX-315 mode of action it is likely that high abundance of tumor cells in the lesion to be injected is necessary for optimal induction of necrosis followed by an immune response targeting the tumor cells.

A previous trial has demonstrated increased CD8+ infiltration following LTX-315 treatment with a prolonged dosing schedule and assessment at 7 weeks after treatment rather than 3 weeks after start of treatment.[19,20] In the present trial, the injected lesions were surgically removed 2 to 5 weeks after start of treatment. We observed increased T-cell infiltration in some samples, but overall the impact of LTX-315 on the injected lesions was lower than reported in previous trials,[19,20] which may be due to short treatment schedule and/or the nature of this hard-to-treat patient population. In one sample (01–1007), we observed high numbers of CD8+ T cells in the infusion product, and IHC data suggest, that CD8+ infiltration increased significantly following LTX-315 treatment. Interestingly, in this patient LTX-315 dose was reduced because of radiological signs of pronounced necrosis which could have an impact of the generation of TIL product. Again, it is difficult to draw conclusions based on a single case, it seems that in this case LTX-315 induced necrosis may be of importance for increasing TILs.

Patient 01–1001 and 01–1007 demonstrated increased number CD3±and CD8+ T cells after treatment, while patient 01–1003 demonstrated the opposite profile. The latter also demonstrated significant necrosis (57–100%) as well as a 2-fold increase in CD4+ cells, which also may present CD4+ macrophages and/or dendritic cells.[37,38] To the best of our knowledge, the impact of these CD4+ non-T cells on the tumor microenvironment is unknown. Patients 01–1004 and 01–1006 had low number of T cells both at baseline and after LTX-315 treatment resulting in unsuccessful generation of TIL products for ACT.

There was no control arm (ACT without LTX-315 treatment) included in the present trial and to our knowledge this is the first trial that has performed ACT using TILs in soft tissue sarcoma patients. However, the feasibility of expanding TILs from sarcomas as well as the performance of functional *in vitro* analyses on these was investigated in a preclinical study.[30] In the preclinical study, tumor samples from 28 patients with 8 different sarcoma subtypes were obtained, and it was possible to expand a minimum of 40 million TILs from 25 of these. Reactivity analyses using ELISPOT revealed reactivity against autologous tumor cells in 11 of 22 tested tumor samples from 7 of 8 different sarcoma subtypes in the preclinical study. In the trial reported here, we were able to expand TILs from only 4 out of 6 patients, but to a higher number than reported previously (mean $51{,}9 \times 10^9$ TILs). Reactivity analysis revealed reactivity against autologous tumor cells in only one out of three tested tumor samples prior to LTX-315 treatment. Following treatment, we observed reactivity against autologous tumor cells in the two patients that did not respond at baseline, suggesting that sarcoma patients indeed may benefit from pretreatment with LTX-315.

In conclusion, this trial is the first to investigate the combination of LTX-315 and ACT. It is also, to the best of our knowledge, the first trial to test TIL-based ACT in patients with metastatic STS. We demonstrate that the combination is safe, and that both LTX-315 alone and in combination with ACT can induce tumor-specific immune responses. In one patient, we observed significant necrosis in the injected lesion combined with high numbers of CD8 + T cells in the infusion product, suggesting that an optimized injection schedule potentially could increase the effect of LTX-315 and thus increase the induced immune response. Even though there were no PR or CR, several of the patients with a progressive disease experienced a stabilization of the disease. Despite the low patient number and short-lasting clinical benefit in this trial, the data are encouraging and add some clinical proof-of-concept evidence that LTX-315 can boost the clonal expansion of T cells that kill tumor cells through a targeted immune response. The treatment schedule could be further optimized to maximize the T-cell infiltration prior to tumor resection.

Translational relevance

LTX-315 is a first-in-class, 9-mer oncolytic peptide of non-viral origin, that in a recent Phase I/II trial was shown to increase tumor infiltrating lymphocytes (TILs) in malignant solid tumors after intratumoral injection. Adoptive cell therapy (ACT) with TILs is a potent treatment that can induce complete and durable anti-tumor responses in patients with melanoma. Patients with advanced soft tissue sarcoma (STS) respond poorly to immunotherapy. In the present trial, LTX-315 was administered intratumorally to patients with advanced STS prior to surgical resection and subsequent *in vitro* expansion of T cells as the first step. In the second step, the expanded

T cells were infused back into the patient following assessment of the antitumor effect. Overall, the trial demonstrates that the combination of LTX-315 and ACT is not only feasible and tolerable, but that tumor-specific T cells can be expanded *in vitro* from tumors that have been pre-treated by LTX-315. The treatment schedule should be further optimized to achieve superior signs of efficacy.

Acknowledgments

We are deeply grateful to patients and their families for their participation and contribution to this trial. We would also like to thank for the support from all co-workers at the National Center for Cancer Immune Therapy (CCIT-DK) with a special thanks to the technicians responsible for TIL expansion at the GMP facility. Thank you to the Department of Oncology, Herlev Hospital, including attending physicians and nurses; The Department of Orthopedic Surgery, Rigshospitalet; Lytix Biopharma; and NEC Oncoimmunity AS.

Disclosure statement

VS, KC, BS and ØR are employees of Lytix Biopharma. KC, BS, and ØR are shareholders in Lytix Biopharma AS. TC and RS are employees in NEC OncoImmunity AS.

IMS has received honoraria for lectures from Novo Nordisk, MSD, Novartis, Pierre Fabre, Sanofi Aventis, BMS, and Takeda. IMS has received consultancy fees from IO Biotech, MSD, Novartis, Pierre Fabre, and TILT Biotherapeutics. IMS institution has received research grants from BMS, IO Biotech, Adaptimmune, Lytix biopharma, Evaxion Biotech, TILT Biotherapeutics, Enara Bio, and Asgard Therapeutics. IMS is shareholder and co-founder of the biotech company IO Biotech ApS.

TJM has received honoraria for a lecture from BMS.

MN has received travel reimbursement from Lytix Biopharma.

Funding

This clinical trial was funded by Lytix Biopharma with support from Norwegian Research Council (Grant number 269814 (Skattefunn 306724), Permides (EU grant VR 102587)

ORCID

Morten Nielsen http://orcid.org/0000-0002-1250-4885
Tine Monberg http://orcid.org/0000-0002-7217-2974
Vibeke Sundvold http://orcid.org/0000-0002-1819-3889
Benedetta Albieri http://orcid.org/0009-0008-3202-5452
Michael Mørk Petersen http://orcid.org/0000-0002-2324-6420
Özcan Met http://orcid.org/0000-0002-3256-7592
Trevor Clancy http://orcid.org/0000-0001-9896-0613
Baldur Sveinbjornsson http://orcid.org/0000-0002-5499-9345
Øystein Rekdal http://orcid.org/0000-0001-5563-6709
Inge Marie Svane http://orcid.org/0000-0002-9451-6037

Data availability statement

The data that support the findings of this study are available from the corresponding author, [author initials], upon reasonable request.

References

1. Frezza AM, Stacchiotti S, Gronchi A. Systemic treatment in advanced soft tissue sarcoma: what is standard, what is new. BMC Med. 2017;15(1):1–12. doi:10.1186/s12916-017-0872-y.
2. Ayodele O, Abdul Razak AR. Immunotherapy in soft-tissue sarcoma. Curr Oncol. 2020;27(February):17–23. doi:10.3747/co.27.5407.
3. Banks LB, D'Angelo SP. The role of immunotherapy in the management of soft tissue sarcomas: Current landscape and future outlook. JNCCN J Natl Compr Cancer Netw. 2022;20(7):834–844. doi:10.6004/jnccn.2022.7027.
4. Birdi HK, Jirovec A, Cortés-Kaplan S, Werier J, Nessim C, Diallo JS, Ardolino M. Immunotherapy for sarcomas: new frontiers and unveiled opportunities. J Immunother Cancer. 2021;9(2):1–12. doi:10.1136/jitc-2020-001580.
5. Granhøj JS, Witness Præst Jensen A, Presti M, Met Ö, Svane IM, Donia M. Tumor-infiltrating lymphocytes for adoptive cell therapy: recent advances, challenges, and future directions. Expert Opin Biol Ther. 2022;22(5):627–641. doi:10.1080/14712598.2022.2064711.
6. Rosenberg SA, Yang JC, Sherry RM, Kammula US, Hughes MS, Phan GQ, Citrin DE, Restifo NP, Robbins PF, Wunderlich JR, et al. Durable complete responses in heavily pretreated patients with metastatic melanoma using T-cell transfer immunotherapy. Clin Cancer Res. 2011;17(13):4550–4557. doi:10.1158/1078-0432.CCR-11-0116.
7. Andersen R, Donia M, Ellebaek E, Borch TH, Kongsted P, Hendel HW, Hölmich LR, Hendel HW, Met Ö, Andersen MH. Long-lasting complete responses in patients with metastatic melanoma after Adoptive cell therapy with tumor-infiltrating lymphocytes and an attenuated IL2 regimen. Clin Cancer Res. 2016;22(15):3734–3745. doi:10.1158/1078-0432.CCR-15-1879.
8. Rohaan MW, Borch TH, van den Berg JH, Met Ö, Kessels R, Geukes Foppen MH, Stoltenborg Granhøj J, Nuijen B, Nijenhuis C, Jedema I, et al. Tumor-infiltrating lymphocyte therapy or ipilimumab in advanced melanoma. N Engl J Med. 2022;387(23):2113–2125. doi:10.1056/NEJMoa2210233.
9. Tran E, Turcotte S, Gros A, Robbins PF, Lu Y, Dudley ME, Parkhurst MR, Yang JC, Rosenberg SA, Hinrichs CS, et al. Cancer immunotherapy based on mutation-specific CD4+ T cells in a patient with epithelial cancer. Sci. 2014;9(80May):641–645. doi:10.1126/science.1251102.
10. Zacharakis N, Chinnasamy H, Black M, Xu H, Lu Y-C, Zheng Z, Pasetto A, Langhan M, Shelton T, Prickett T, et al. Immune recognition of somatic mutations leading to complete durable regression in metastatic breast cancer. Nat Med. 2018;24(6):724–730. doi:10.1038/s41591-018-0040-8.
11. Stevanović S, Draper LM, Langhan MM, Campbell TE, Kwong ML, Wunderlich JR, Dudley ME, Yang JC, Sherry RM, Kammula US, et al. Complete regression of metastatic cervical cancer after treatment with human papillomavirus-targeted tumor-infiltrating T cells. J Clin Oncol. 2015;33(14):1543–1550. doi:10.1200/JCO.2014.58.9093.
12. Kverneland AH, Pedersen M, Wulff Westergaard MC, Nielsen M, Borch TH, Olsen LR, Aasbjerg G, Santegoets SJ, van der Burg SH, Milne K, et al. Adoptive cell therapy in combination with checkpoint inhibitors in ovarian cancer. Oncotarget. 2020;11(22):2092–2105. doi:10.18632/oncotarget.27604.
13. Kverneland AH, Chamberlain CA, Borch TH, Nielsen M, Mørk SK, Kjeldsen JW, Lorentzen CL, Jørgensen LP, Riis LB, Yde CW, et al. Adoptive cell therapy with tumor-infiltrating lymphocytes supported by checkpoint inhibition across multiple solid cancer types. J Immunother Cancer. 2021;9(10):1–11. doi:10.1136/jitc-2021-003499.
14. Haug BE, Camilio KA, Eliassen LT, Stensen W, Svendsen JS, Berg K, Mortensen B, Serin G, Mirjolet JF, Bichat F, et al. Discovery of a 9-mer cationic peptide (LTX-315) as a potential first in class oncolytic peptide. J Med Chem. 2016;59(7):2918–2927. doi:10.1021/acs.jmedchem.5b02025.
15. Sveinbjørnsson B, Camilio KA, Haug BE, Rekdal Ø. LTX-315: a first-in-class oncolytic peptide that reprograms the tumor microenvironment. Futur Med Chem. 2017;9(12):1339–1344. doi:10.4155/fmc-2017-0088.

16. Camilio KA, Berge G, Ravuri CS, Rekdal Ø, Sveinbjørnsson B. Complete regression and systemic protective immune responses obtained in B16 melanomas after treatment with LTX-315. Cancer Immunol Immunother. 2014;63(6):601–613. doi:10.1007/s00262-014-1540-0.
17. Nestvold J, Wang MY, Camilio KA, Zinöcker S, Tjelle TE, Lindberg A, Haug BE, Kvalheim G, Sveinbjørnsson B, Rekdal Ø. Oncolytic peptide LTX-315 induces an immune-mediated abscopal effect in a rat sarcoma model. Oncoimmunology. 2017;6(8):1–12. doi:10.1080/2162402X.2017.1338236.
18. Liao HW, Garris C, Pfirschke C, Rickelt S, Arlauckas S, Siwicki M, Kohler RH, Weissleder R, Sundvold-Gjerstad V, Sveinbjørnsson B, et al. LTX-315 sequentially promotes lymphocyte-independent and lymphocyte-dependent antitumor effects. Cell Stress. 2019;3 (11):348–360. doi:10.15698/cst2019.11.204.
19. Jebsen NL, Apelseth TO, Haugland HK, Rekdal Ø, Patel H, Gjertsen BT, Jøssang DE. Enhanced T-lymphocyte infiltration in a desmoid tumor of the thoracic wall in a young woman treated with intratumoral injections of the oncolytic peptide LTX-315: a case report. J Med Case Reports. 2019;13(1):1–9. doi:10.1186/s13256-019-2088-6.
20. Spicer J, Marabelle A, Baurain JF, Jebsen NL, Jøssang DE, Awada A, Kristeleit R, Loirat D, Lazaridis G, Jungels C, et al. Safety, antitumor activity, and T-cell responses in a dose-ranging phase I trial of the oncolytic peptide LTX-315 in patients with solid tumors. Clin Cancer Res. 2021;27(10):2755–2763. doi:10.1158/1078-0432.CCR-20-3435.
21. World Medical Association. World medical association declaration of Helsinki: ethical principles for medical research involving human subjects. JAMA. 2013;310(20):2191–2194. doi:10.1001/jama.2013.281053.
22. Dudley ME, Wunderlich JR, Yang JC, Sherry RM, Topalian SL, Restifo NP, Royal RE, Kammula U, White DE, Mavroukakis SA, et al. Adoptive cell transfer therapy following non-myeloablative but lymphodepleting chemotherapy for the treatment of patients with refractory metastatic melanoma. J Clin Oncol. 2005;23 (10):2346–2357. doi:10.1200/JCO.2005.00.240.
23. Ellebaek E, Iversen TZ, Junker N, Donia M, Engell-Noerregaard L, Met O, Hölmich LR, Andersen RS, Hadrup SR, Andersen MH, et al. Adoptive cell therapy with autologous tumor infiltrating lymphocytes and low-dose interleukin-2 in metastatic melanoma patients. J Transl Med. 2012;10(1):169. doi:10.1186/1479-5876-10-169.
24. Eisenhauer E, Therasse P, Bogaerts J, Schwartz LH, Sargent D, Ford R, Dancey J, Arbuck S, Gwyther S, Mooney M, et al. New response evaluation criteria in solid tumours: revised RECIST guideline (version 1.1). Eur J Cancer. 2009;45(2):228–247. doi:10.1016/j.ejca.2008.10.026.
25. Tran KQ, Zhou J, Durflinger KH, Langhan MM, Shelton TE, Wunderlich JR, Robbins PF, Rosenberg SA, Dudley ME. Minimally cultured tumor-infiltrating lymphocytes display optimal characteristics for adoptive cell therapy. J Immunother (1991). 2008;31(8):742–751. doi:10.1097/CJI.0b013e31818403d5.
26. Donia M, Junker N, Ellebaek E, Andersen MH, Straten PT, Svane IM. Characterization and comparison of 'standard' and 'Young' tumour-infiltrating lymphocytes for Adoptive cell therapy at a Danish translational research institution. Scand J Immunol. 2011;75(2):157–167. doi:10.1111/j.1365-3083.2011.02640.x.
27. Donia M, Larsen SM, Met O, Svane IM. Simplified protocol for clinical-grade tumor-infiltrating lymphocyte manufacturing with use of the wave bioreactor. Cytotherapy. 2014;16(8):1117–1120. doi:10.1016/j.jcyt.2014.02.004.
28. DeWitt WS, Emerson RO, Lindau P, Vignali M, Snyder TM, Desmarais C, Sanders C, Utsugi H, Warren EH, McElrath J, et al. Dynamics of the cytotoxic T cell response to a model of acute viral infection. J Virol. 2015;89(8):4517–4526. doi:10.1128/jvi.03474-14.
29. Rytlewski J, Deng S, Xie T, Davis C, Robins H, Yusko E, Bienkowska J, Beavis PA. Model to improve specificity for identification of clinically-relevant expanded T cells in peripheral blood. PLos One. 2019;14(3):1–10. doi:10.1371/journal.pone.0213684.
30. Nielsen M, Krarup-Hansen A, Hovgaard D, Petersen MM, Loya AC, Westergaard MCW, Svane IM, Junker N. In vitro 4-1BB stimulation promotes expansion of CD8+ tumor-infiltrating lymphocytes from various sarcoma subtypes. Cancer Immunol Immunother. 2020;69(11):2179–2191. doi:10.1007/s00262-020-02568-x.
31. Tawbi HA, Burgess M, Bolejack V, Van Tine BA, Schuetze SM, Hu J, Angelo SD, Attia S, Riedel RF, Priebat DA, et al. Pembrolizumab in advanced soft-tissue sarcoma and bone. Lancet Oncol. 2017;2045(17):1–9. doi:10.1016/S1470-2045(17)30624-1.
32. Somaiah N, Conley AP, Parra ER, Lin H, Amini B, Solis Soto L, Salazar R, Barreto C, Chen H, Gite S, et al. Durvalumab plus tremelimumab in advanced or metastatic soft tissue and bone sarcomas: a single-centre phase 2 trial. Lancet Oncol. 2022;23 (9):1156–1166. doi:10.1016/S1470-2045(22)00392-8.
33. Utsugi T, Schroit AJ, Connor J, Bucana CD, Fidler IJ. Elevated expression of phosphatidylserine in the outer membrane leaflet of human tumor cells and recognition by activated human blood monocytes. Cancer Res. 1991;51:3062–3066.
34. Gaspar D, Salomé Veiga A, Castanho MARB. From antimicrobial to anticancer peptides. A review. Front Microbiol. 2013;4 (OCT):1–16. doi:10.3389/fmicb.2013.00294.
35. Yao X, Ahmadzadeh M, Lu YC, Liewehr DJ, Dudley ME, Liu F, Schrump DS, Steinberg SM, Rosenberg SA, Robbins PF. Levels of peripheral CD4+FoxP3+ regulatory T cells are negatively associated with clinical response to adoptive immunotherapy of human cancer. Blood. 2012;119(24):5688–5696. doi:10.1182/blood-2011-10-386482.
36. Dudley ME, Yang JC, Sherry R, Hughes MS, Royal R, Kammula U, Robbins PF, Huang J, Citrin DE, Leitman SF, et al. Adoptive cell therapy for patients with metastatic melanoma: evaluation of intensive myeloablative chemoradiation preparative regimens. J Clin Oncol. 2008;26(32):5233–5239. doi:10.1200/JCO.2008.16.5449.
37. Patterson S, Gross J, English N, Stackpoole A, Bedford P, Knight SC. CD4 expression on dendritic cells and their infection by human immunodeficiency virus. J Gen Virol. 1995;76 (5):1155–1163. doi:10.1099/0022-1317-76-5-1155.
38. Collin M, Herbein G, Montaner L, Gordon S. PCR analysis of HIV1 infection of macrophages: virus entry is CD4-dependent. Res Virol. 1993;144(C):13–19. doi:10.1016/S0923-2516(06)80006-3.