Downloaded from orbit.dtu.dk on: Apr 27, 2024

DTU Library

# Laser-assisted topical delivery of vismodegib reduces hedgehog gene expression in human basal cell carcinomas in vivo

**Olesen, Uffe H.; Pedersen, Kristian Kåber; Togsverd-Bo, Katrine; Biskup, Edyta; Nielsen, Anni Linnet; Jackerott, Malene; Clergeaud, Gael; Andresen, Thomas L.; Haedersdal, Merete**

*Published in:*
Lasers in Surgery and Medicine

*Link to article, DOI:*
10.1002/lsm.23766

*Publication date:*
2024

*Document Version*
Publisher's PDF, also known as Version of record

Link back to DTU Orbit

*Citation (APA):*
Olesen, U. H., Pedersen, K. K., Togsverd-Bo, K., Biskup, E., Nielsen, A. L., Jackerott, M., Clergeaud, G., Andresen, T. L., & Haedersdal, M. (2024). Laser-assisted topical delivery of vismodegib reduces hedgehog gene expression in human basal cell carcinomas in vivo. *Lasers in Surgery and Medicine*, *56*(3), 239-248. https://doi.org/10.1002/lsm.23766

**General rights**
Copyright and moral rights for the publications made accessible in the public portal are retained by the authors and/or other copyright owners and it is a condition of accessing publications that users recognise and abide by the legal requirements associated with these rights.

- Users may download and print one copy of any publication from the public portal for the purpose of private study or research.
- You may not further distribute the material or use it for any profit-making activity or commercial gain
- You may freely distribute the URL identifying the publication in the public portal

If you believe that this document breaches copyright please contact us providing details, and we will remove access to the work immediately and investigate your claim.

Check for updates

Accepted: 22 January 2024

DOI: 10.1002/lsm.23766

CLINICAL REPORT

# Laser-assisted topical delivery of vismodegib reduces hedgehog gene expression in human basal cell carcinomas in vivo

**Uffe H. Olesen PhD[1] | Kristian Kåber Pedersen MSc[1] | Katrine Togsverd-Bo PhD[1] | Edyta Biskup PhD[2] | Anni Linnet Nielsen PhD[3] | Malene Jackerott PhD[4] | Gael Clergeaud PhD[5] | Thomas L. Andresen PhD[5] | Merete Haedersdal DMSc[1,6]**

[1]Department of Dermatology, Copenhagen University Hospital—Bispebjerg, Copenhagen, Denmark

[2]Department of Pathology, Copenhagen University Hospital—Herlev, Herlev, Denmark

[3]Department of Oncology, Copenhagen University Hospital—Herlev, Herlev, Denmark

[4]Leo Pharma A/S, Ballerup, Denmark

[5]Department of Health Technology, Technical University of Denmark, Lyngby, Denmark

[6]Department of Clinical Medicine, Copenhagen University, Copenhagen, Denmark

**Correspondence**

Uffe H. Olesen, PhD, Department of Dermatology, Copenhagen University Hospital—Bispebjerg, D92, Nielsine Nielsens vej 17, DK-2400 Copenhagen, Denmark.
Email: Olesen.uh@gmail.com

## Abstract

**Background:** Systemically delivered hedgehog inhibitors including vismodegib and sonidegib are widely used to treat basal cell carcinomas (BCCs). Ablative fractional laser (AFL)-assisted topical delivery of vismodegib has been demonstrated in preclinical studies. The aim of this explorative clinical study was to evaluate intratumoral vismodegib concentrations and effect on hedgehog pathway gene expression following AFL-assisted topical vismodegib delivery to BCCs.

**Methods:** In an open-label clinical trial, 16 nodular BCCs (in $n = 9$ patients) received one application of $CO_2$-AFL (40 mJ/microbeam, 10% density) followed by topical vismodegib emulsion. After 3–4 days, vismodegib concentrations in tumor biopsies ($n = 15$) and plasma were analyzed and compared with samples from patients receiving oral treatment ($n = 3$). GLI1, GLI2, PTCH1, and PTCH2 expression was determined by quantitative polymerase chain reaction ($n = 7$) and GLI1 additionally by in situ hybridization ($n = 3$).

**Results:** Following AFL-assisted topical administration, vismodegib was detected in 14/15 BCCs and reached a median concentration of 6.2 μmol/L, which compared to concentrations in BCC tissue from patients receiving oral vismodegib (9.5 μmol/L, $n = 3$, $p = 0.8588$). Topical vismodegib reduced intratumoral GLI1 expression by 51%, GLI2 by 55%, PTCH1 and PTCH2 each by 73% ($p \leq 0.0304$) regardless of vismodegib concentrations ($p \geq 0.3164$). In situ hybridization demonstrated that GLI1 expression was restricted to tumor tissue and downregulated in response to vismodegib exposure.

**Conclusion:** A single AFL-assisted topical application of vismodegib resulted in clinically relevant intratumoral drug concentrations and significant reductions in hedgehog pathway gene expressions.

KEYWORDS

ablative fractional laser, basal cell carcinoma, clinical trial, emulsion drug formulation, laser-assisted drug delivery, vismodegib

This is an open access article under the terms of the Creative Commons Attribution-NonCommercial-NoDerivs License, which permits use and distribution in any medium, provided the original work is properly cited, the use is non-commercial and no modifications or adaptations are made.
© 2024 The Authors. *Lasers in Surgery and Medicine* published by Wiley Periodicals LLC.

# INTRODUCTION

Hedgehog inhibitors emerged in 2012 as the first class of drugs approved specifically for the treatment of locally advanced and metastatic basal cell carcinoma (BCC) as vismodegib received approval from the US Food and Drug Administration.[1,2] Hedgehog inhibitors target aberrant activation of hedgehog pathway signaling that is observed in practically all BCCs and appears crucial for tumor development.[3] All currently approved hedgehog inhibitors, including vismodegib and sonidegib, are administered systemically.[4,5] The potential clinical impact of hedgehog inhibitor treatment is substantial but considerable adverse effects related to systemic hedgehog inhibition lead to frequent treatment interruptions or discontinuations and with that, reduced efficacy.[5–7] In addition, the risk of adverse effects increases with treatment duration,[8] underlining the challenge of systemic hedgehog inhibition.

To reduce the risk of systemic adverse effects, hedgehog inhibitors could be delivered locally.[9–12] A safe, topical administration might reduce the risk of treatment interruption due to adverse effects and thus potentially broaden the range of applications for hedgehog inhibitors beyond locally advanced and metastatic BCC.[13] Topical hedgehog inhibitor delivery has been explored in preclinical studies with promising results in terms of biological response and tumor remission.[14] Currently, only a few clinical trials have been conducted on topical hedgehog inhibitor therapy, and overall studies do not show conclusive results in line with preclinical work.[14] A significant challenge in clinical trials is that it remains to be determined whether hedgehog inhibitors reach sufficient concentrations in tumor tissue. To date, intratumoral hedgehog inhibitor concentrations of BCC have not been determined in patients for neither systemic nor topical administration.[14]

Ablative fractional laser (AFL) has been widely shown in preclinical and clinical studies to enhance the uptake of topically applied drugs by providing a grid of microchannels that facilitate drug diffusion across the skin barrier.[15–17] The concept may also be used to provide topical delivery of drugs that are otherwise delivered systemically,[18–23] which has also been demonstrated in a clinical setting for BCC treatment.[24] We have previously described AFL-assisted topical delivery of a vismodegib emulsion in preclinical studies, which led to high cutaneous vismodegib concentrations in healthy porcine skin.[25,26] We hypothesized that AFL could deliver vismodegib into human BCCs, achieving sufficient drug concentrations to elicit a biological tumor response. Accordingly, in this explorative clinical study, we aimed to investigate AFL-assisted vismodegib delivery in nodular BCCs by evaluating intratumoral vismodegib concentrations and assessing the impact on hedgehog pathway gene expression.

# MATERIALS AND METHODS

## Study design

The open-label good clinical practice monitored explorative study included patients ($n = 9$) with 1–3 nodular BCCs each. The study protocol was approved by the competent national ethics committee (H-19038262), the Danish Medicines Agency (2019-002545-38; EudraCT trial registration number 2019-002545-38, date September 13, 2019), and the Danish Data Protection Agency. Informed consent was obtained from all patients before being included in the study. The study was conducted from September 2020 to December 2021.

On the day of intervention, BCCs were exposed to a single treatment consisting of AFL exposure followed by the application of topical vismodegib emulsion (Figure 1). At a follow-up visit on Days 3 and 4, BCCs were evaluated for local skin responses, then punch skin tumor biopsies (up to three: one 4 mm, one 3 mm, and one 2 mm) and plasma samples were collected for detection of intratumoral vismodegib by mass spectrometry and expression of hedgehog pathway genes (GLI1, GLI2, PTCH1, and PTCH2) relative to pretreatment levels (determined from tumor biopsies taken ≥4 weeks before day of treatment intervention to avoid any influence on study results from wound healing). Vismodegib concentrations were compared to tumor and plasma samples obtained from patients receiving systemic vismodegib.

## Patients and BCCs

Nine patients with histologically verified nodular BCC ($n = 16$, Table 1) were recruited and treated at the Department of Dermatology at Bispebjerg University Hospital, Denmark. Inclusion criteria were 18 years of age or older, signed informed consent, biopsy-proven nodular BCC > 8 mm diameter, and adherence to safe contraceptive measures. Exclusion criteria were pregnancy (by human chorionic gonadotropin test for fertile women) or lactation, topical use of hedgehog-pathway inhibitors (e.g., ketoconazole, imiquimod), infiltrative BCC tumor tissue, and history of porphyria or hypertrophic scarring, to minimize the risk of rare adverse events potentially relevant in these specific patient populations.

## Vismodegib emulsion

The oil-in-water vismodegib emulsion was produced as previously described,[26] Briefly, content from two vismodegib capsules (Erivedge, equal to 300 mg vismodegib) was dissolved in dimethyl sulfoxide and soybean oil (3% and 10% v/v of total volume, respectively), yielding the

10969101, 2024, 3, Downloaded from https://onlinelibrary.wiley.com/doi/10.1002/lsm.23766 by Danish Technical Knowledge, Wiley Online Library on [26/03/2024]. See the Terms and Conditions (https://onlinelibrary.wiley.com/terms-and-conditions) on Wiley Online Library for rules of use; OA articles are governed by the applicable Creative Commons License

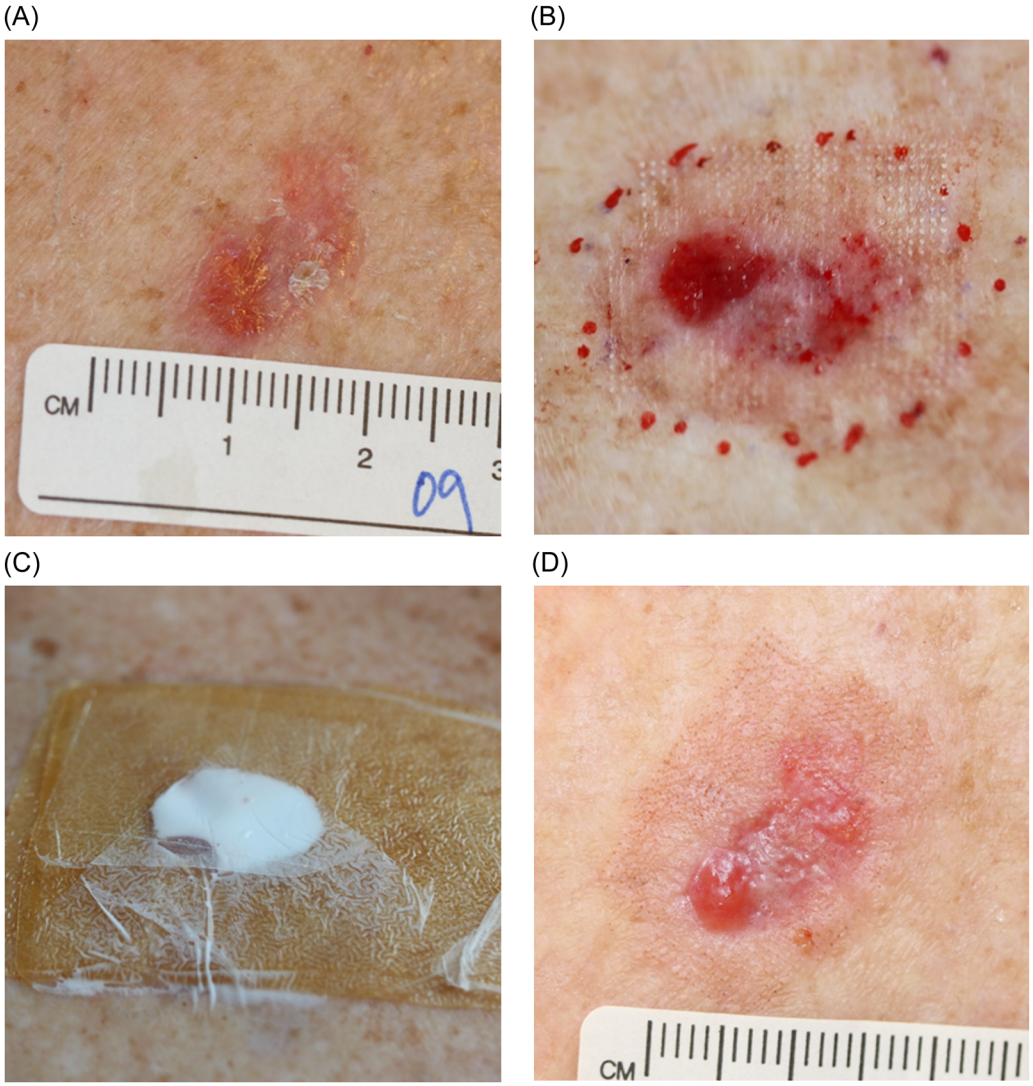


**FIGURE 1** Procedural and local skin reactions for topical administration of vismodegib by AFL. Images of a representative tumor before treatment (A), following AFL exposure, tumor margin marked in red (B), during 4-h topical vismodegib administration (C), and at follow-up after 4 days, before biopsies are taken (D). Local skin reactions primarily consisted of moderate erythema and mild edema. AFL, ablative fractional laser.

**TABLE 1** Demographic patient data and tumor information.

| | Patients | | | | Histologically verified nodular basal cell carcinomas | | | | | |
|---|---|---|---|---|---|---|---|---|---|---|
| **Administration route** | ***n*** | **Age (years)** | **Sex (%)** | | ***n*** | **Localization (%)** | | **Ulcerated (%)** | | **Tumor size ($mm^2$)** |
| Topical | 9 | 76 (58–91) | Male | 67 | 16 | Trunk | 81 | Yes | 25 | 154 (98–252) |
| | | | Female | 33 | | Limbs | 19 | No | 75 | |
| | | | | | | Head | 0 | | | |
| Systemic | 3 | 73 (68–85) | Male | 0 | 3 | Trunk | 33 | Yes | 0 | 118 (106–766) |
| | | | Female | 100 | | Limbs | 0 | No | 100 | |
| | | | | | | Head | 67 | | | |

*Note*: Age is reported as median and range. Tumor size was calculated as length × breadth × $\pi$ × 0.25 and is reported as median with interquartile range.

10969101, 2024, 3, Downloaded from https://onlinelibrary.wiley.com/doi/10.1002/lsm.23766 by Danish Technical Knowledge, Wiley Online Library on [26/03/2024]. See the Terms and Conditions (https://onlinelibrary.wiley.com/terms-and-conditions) on Wiley Online Library for rules of use; OA articles are governed by the applicable Creative Commons License

oil phase. The aqueous phase consisted of 0.5% w/v Tween-80 in PBS (10 mM, pH 7.4). The two phases were mixed using a probe sonicator and sediment-free emulsion was used for the study. The emulsion was produced at a good manufacturing practice-certified facility at Copenhagen University Hospital. Vismodegib concentration of the emulsion was determined to be 3.8 mg/mL. Aqueous solutions such as emulsions appear optimal for laser-assisted drug delivery and minimal local skin reactions have been reported from application of the emulsion in preclinical studies.[25,27]

## Topical study intervention

For the topical intervention, each BCC was demarcated at a 5 mm margin and documented with standardized clinical photographs (Canon 750D; Canon). In local anesthesia with carbocaine and adrenaline (20 + 5 mg/mL), the BCC and surrounding margin were treated with an Ultrapulse® fractional 10,600 nm $CO_2$ laser with a DeepFx handpiece (Lumenis Inc.) at 40 mJ/microbeam at 10% density in a single pass. Setting selection was based on a pilot study that identified fluences minimized tumor bleeding and oozing as compared to previously applied settings for topical vismodegib delivery in healthy porcine skin (80 mJ/microbeam at 5% density).[25] Topical anesthesia was deemed insufficient for the present study and local anesthesia was selected even if this strategy could potentially increase the risk of adverse reactions[28]; no such adverse reactions were observed. Adrenaline has a potential temporal impact on cutaneous drug retention due to vasoconstriction,[29] but the effect would likely be minimal on Days 3 and 4. A customized well of hydroactive bandage (DuoDerm Ultrathin Hydroactive™; ConvaTec) sealed with transparent film dressing (TegaDerm® film dressing; 3M Medical) covered BCC and margin. Vismodegib emulsion was injected into the well (approximately 0.25 mL vismodegib emulsion/$cm^2$ well). The emulsion was removed after 4 h using a syringe and the bandage was left on until Day 3 or 4 posttreatment.

## Follow-up evaluation

On a follow-up visit on Day 3 or 4, local skin reactions of the treatment area were photo-documented and assessed (including the presence of erythema, edema, crusting, flaking, erosion, oozing, and fibrin formation evaluated using arbitrary scales: 0: no signs, 1: mild, 2: moderate, and 3: severe). In addition, patients were allowed to self-report any adverse events encountered. Subsequently, up to three biopsies (depending on tumor size) were sampled from each BCC: a 4 mm punch biopsy to determine intratumoral vismodegib concentration ($n = 15$), a 2 mm punch biopsy for quantitative biological response ($n = 7$) and a 3 mm punch biopsy for in situ hybridization-based GLI1 assessment ($n = 3$). Biopsies were prioritized in the following order: vismodegib concentration > quantitative hedgehog pathway gene expression > GLI1 in situ hybridization. Numbers of biopsies required were estimated from previous preclinical and clinical studies.[1,24,25] Plasma was isolated from full blood of each patient and used for the determination of total plasma vismodegib concentration. Biopsies used to determine vismodegib concentrations were weighed as a measure of biopsy volume. Protocols for mass spectrometry analysis of vismodegib (intratumoral and plasma concentrations) as well as quantitative and qualitative evaluation of hedgehog pathway gene expression can be found in Supporting Information.

Following the visit, residual BCC tumor was subsequently removed by surgical excision, curettage with cautery, or radiation therapy according to national standard practice and the individual patient's treatment preference.

## Patients and procedures for systemic vismodegib intervention

Three patients receiving systemic vismodegib treatment with 150 mg vismodegib daily and with histologically verified nodular BCC tumor tissue >5 mm were included as a control group. In addition, the inclusion and exclusion criteria for topical vismodegib administration were applied. Patients had received systemic vismodegib treatment for a minimum of 28 days at the time of inclusion to ensure steady-state plasma concentrations. After inclusion, a 3 mm punch biopsy and a 4 mL blood sample were obtained to determine intratumoral and total plasma vismodegib concentration, respectively. Vismodegib treatment regimen was not altered before, during, or after study inclusion, and local guidelines were applied for continued follow-up visits.

## Statistics

Statistics were performed using GraphPad Prism 9.3.1 (GraphPad Software). Normal distribution of data was tested using Shapiro–Wilk tests and subsequently comparisons were performed using two-tailed $t$ tests or Mann–Whitney tests depending on whether data were normally distributed. Outliers were identified using Grubb's test with an alpha of 0.05. The level of statistical significance was set at $p \leq 0.05$. Correlations were determined using Pearson's correlation coefficients.

10969101, 2024, 3, Downloaded from https://onlinelibrary.wiley.com/doi/10.1002/lsm.23766 by Danish Technical Knowledge, Wiley Online Library on [26/03/2024]. See the Terms and Conditions (https://onlinelibrary.wiley.com/terms-and-conditions) on Wiley Online Library for rules of use; OA articles are governed by the applicable Creative Commons License

# RESULTS

## Mass-spectrometry assessed vismodegib concentrations

Vismodegib was detected on Days 3 and 4 in 14/15 BCC following a single administration of AFL-assisted topical vismodegib (Figure 2), reaching intratumoral concentration median of 6.2 µmol/L (Table 2). Although 25% of tumors were ulcerated before intervention (Table 2), no difference in drug uptake could be identified between ulcerated and nonulcerated tumors ($p = 0.3681$). Vismodegib concentrations measured in BCCs treated systemically were comparable to topical vismodegib uptake (6.2 vs. 9.5 µmol/L, $p = 0.8588$). For systemic administration, plasma vismodegib concentrations were similar to corresponding intratumoral concentrations (8.9 µmol/L, $p = 0.8482$, Figure 2 and Table 2).

## Quantitative and qualitative evaluation of impact on hedgehog pathway gene expression

Vismodegib deposited by the topical administration system induced a substantial biological response in BCCs, based on the impact on hedgehog pathway genes (Figure 3). Intratumoral hedgehog gene expression levels were reduced by 51% for GLI1, 55% for GLI 2%, and 73% for both PTCH1 and PTCH2, compared to baseline levels ($p = 0.0092$–$0.0304$, Table 2). The reductions in hedgehog pathway gene expression did not correlate with intratumoral vismodegib concentrations (Figure 4, $p = 0.3164$–$0.6772$) and did not appear to vary between ulcerated and nonulcerated tumors ($p = 0.0648$–$0.4734$).

Before treatment, in situ hybridization demonstrated that GLI1 mRNA was localized to tumor cells and not in the surrounding healthy tissue (Figure 5A,B). AFL-assisted topical vismodegib administration decreased intratumoral GLI1 expression, visualized by the lower density of GLI1 positive dots in tumor areas of the skin (Figure 5C,D).

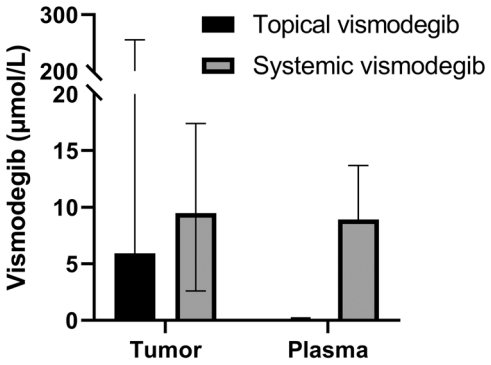


**FIGURE 2** Vismodegib concentrations in tumor and plasma. Intratumoral and plasma concentrations for ablative fractional laser-assisted topical- and systemic vismodegib treatment. Concentrations for topical administration were assessed 3–4 days after treatment while concentrations for systemic treatment were determined at steady-state levels (>28 days after treatment initiation). Data are shown as medians with interquartile ranges. Topical vismodegib: tumor samples ($n = 15$), plasma ($n = 9$). Systemic vismodegib: tumor samples ($n = 3$) and plasma ($n = 3$).

## Safety

AFL-assisted topical vismodegib administration was well tolerated. Overall, patients showed moderate erythema with mild edema and oozing, consistent with the AFL treatment (Table 3). Severe erythema was observed in a single patient while no infections occurred throughout the study. No systemic uptake of vismodegib following topical administration was observed when drug plasma levels were assessed (Figure 2 and Table 2) and no additional adverse events occurred.

# DISCUSSION

Only two published clinical trials have previously investigated topical delivery of approved hedgehog inhibitors in BCC patients, and none report intratumoral drug uptake. This explorative clinical trial is thus the first to demonstrate that topical vismodegib can achieve intratumoral concentrations comparable to systemic administration, with a favorable safety profile. We further show that AFL-assisted topical vismodegib administration produced a substantial biological response, based on the reduction of four hedgehog pathway genes. To our knowledge, the study is the first to show that altering drug

**TABLE 2** Vismodegib concentrations and hedgehog pathway gene expressions.

| | Vismodegib concentrations (µmol/L) | | Reduction in gene expression (%) | | | |
|---|---|---|---|---|---|---|
| Administration route | Tumor | Plasma | GLI1 | GLI2 | PTCH1 | PTCH2 |
| Topical | 6.2 (2.1–249.1) | 0.0 (0.0–0.0) | 51 (14–94), $p = 0.0163$ | 55 (18–93), $p = 0.0235$ | 73 (17–92), $p = 0.0304$ | 73 (6–85), $p = 0.0092$ |
| Systemic | 9.5 (2.6–17.4) | 8.9 (8.8–13.7) | NA | | | |

*Note*: Vismodegib concentrations are calculated based on volume of tumor biopsy or plasma sample. Gene expression is presented reduction in percent following treatment. Data are reported as medians with interquartile ranges.

Abbreviation: NA, not applicable.

10969101, 2024, 3, Downloaded from https://onlinelibrary.wiley.com/doi/10.1002/lsm.23766 by Danish Technical Knowledge, Wiley Online Library on [26/03/2024]. See the Terms and Conditions (https://onlinelibrary.wiley.com/terms-and-conditions) on Wiley Online Library for rules of use; OA articles are governed by the applicable Creative Commons License

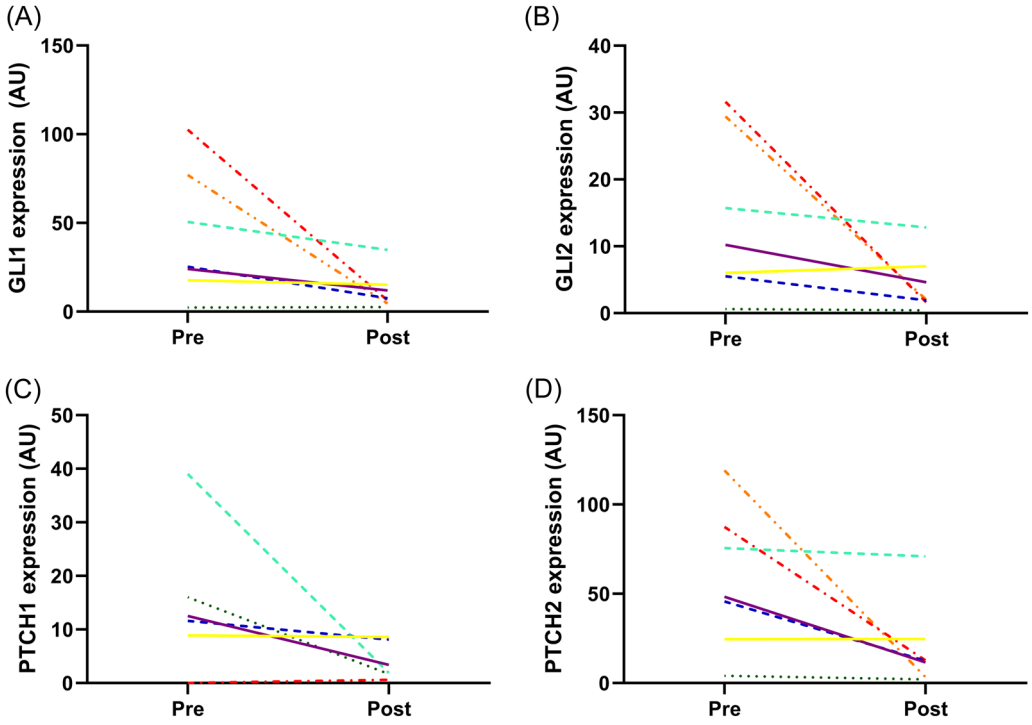


**FIGURE 3** Intratumoral hedgehog pathway gene expression before and after ablative fractional laser-assisted topical vismodehib delivery. Expression levels of GLI (A), GLI1 (B), PTCH1 (C), and PTCH2 (D) in tumor biopsies before (pre) and 3–4 days after (post) treatment. Colors represent individual tumors and show a similar pattern between the four genes. Units on *y*-axis are arbitrary units (AU).

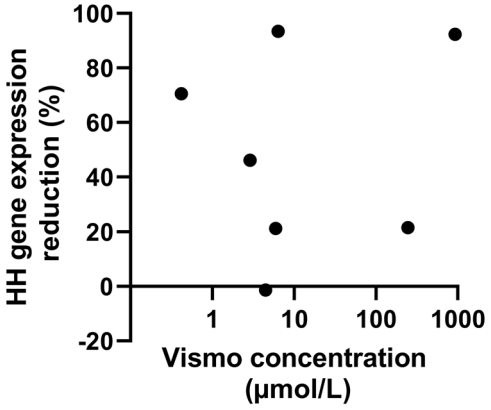


**FIGURE 4** Correlation between intratumoral vismodegib concentrations and reduction of HH pathway gene expression. Plot of HH pathway gene expression reduction (GLI1, GLI2, PTCH1, and PTCH2 combined) versus intratumoral vismodegib concentrations following ablative fractional laser-assisted topical vismodegib administration, with a correlation coefficient of 0.4243. Correlation coefficients for individual genes were 0.4455, 0.4206, 0.3535, and 0.1937 for GLI1, GLI2, PTCH1, and PTCH2, respectively. *y*-axis is linear, and *x*-axis is on a $\log_{10}$ scale. HH, hedgehog.

administration from oral to topical by AFL-assisted drug delivery can still elicit an appropriate biological response in the target tissue of humans. Together, our results support the clinical potential of AFL-assisted topical vismodegib delivery as stand-alone or adjuvant therapy for nodular BCCs.

Importantly, AFL enabled intratumoral vismodegib concentrations that were still detectable by Day 4, albeit in a broad concentration range between tumors. However, to maintain clinically relevant drug levels for the duration typically needed for BCCs, reapplication of topical vismodegib is likely required. Accordingly, additional studies are required to determine the frequency of vismodegib reapplication needed to support the continuous presence of intratumoral vismodegib. Future studies would further benefit from establishing intratumoral spatial biodistribution of vismodegib as laser-assisted drug delivery tends to yield the highest concentrations closest to the skin surface.[20,21,24,30]

Routinely reported in pharmacokinetic studies, plasma concentrations have served as a proxy for vismodegib tissue deposition[4,25,26] but the relationship between plasma and tumor tissue concentrations has not previously been substantiated. Our preliminary data suggests that concentrations in plasma and BCCs are comparable after systemic vismodegib, which may establish plasma concentrations as a viable surrogate for intratumoral vismodegib accumulation. Notably though, as the median plasma vismodegib concentration of 9.5 µmol/L in the present study is at the lower end of the steady-state concentration range previously determined for oral vismodegib treatment (5.5–56.9 µmol/L),[4] a larger patient cohort could further resolve the relationship between plasma and intratumoral concentrations.

10969101, 2024, 3, Downloaded from https://onlinelibrary.wiley.com/doi/10.1002/lsm.23766 by Danish Technical Knowledge, Wiley Online Library on [26/03/2024]. See the Terms and Conditions (https://onlinelibrary.wiley.com/terms-and-conditions) on Wiley Online Library for rules of use; OA articles are governed by the applicable Creative Commons License

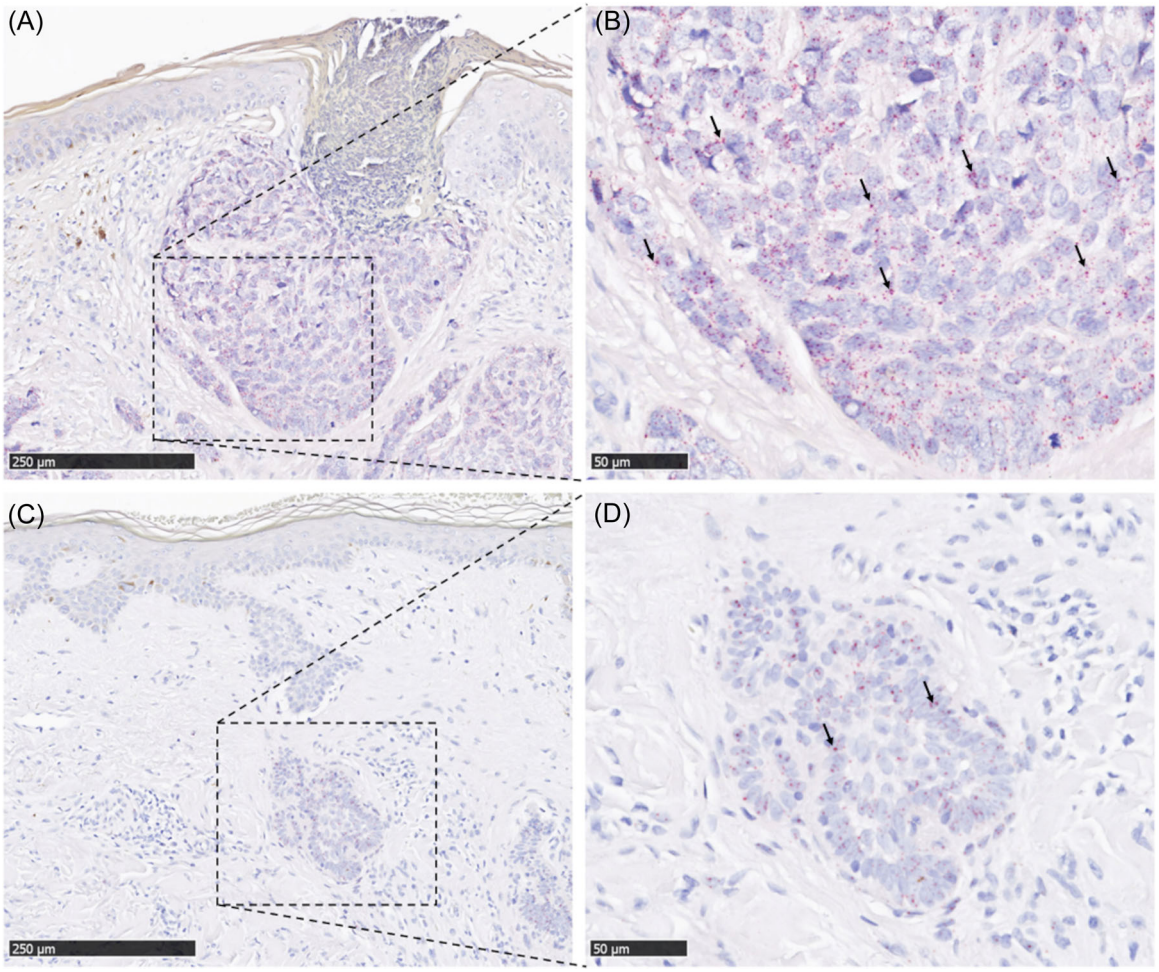


**FIGURE 5** Localization of GLI1 mRNA in histological sections of BCC before and after topical vismodegib treatment. RNAscope in situ hybridization for GLI1 mRNA in skin biopsies from the same BCC skin lesion obtained from a patient before (A) and (B) or four days after (C) and (D) ablative fractional laser-assisted topical vismodegib administration. The density of the GLI1 positive red dots (examples indicated by arrows) in tumor areas of the skin section is clearly lower after (D) than before (B) vismodegib treatment. In the images presented, quantitative image analysis of the area of all GLI positive dots in relation to the total area of tumor cells showed 37% reduced density of GLI1 signal in tumor areas after treatment with vismodegib (D) compared to before treatment (B). BCC, basal cell carcinoma; mRNA, messenger RNA.

**TABLE 3** Local skin reactions on Days 3 and 4 following ablative fractional laser-assisted topical vismodegib administration.

| Degree | Erythema | Edema | Crusting | Flaking | Erosion | Oozing | Fibrin formation |
|---|---|---|---|---|---|---|---|
| 0: No signs<br>1: Mild<br>2: Moderate<br>4: Severe | 2 (2–2) | 1 (1–1) | 0 (0–0) | 0 (0–0) | 0 (0–0.3) | 1 (0–1) | 0 (0–0) |

*Note*: Numbers are reported as medians with interquartile ranges.

To substantiate the potential therapeutic rationale of topical vismodegib administration by AFL, we investigated its biological response in BCC, based on the impact on hedgehog pathway gene expression which is upregulated in BCCs. We found that expression levels of all evaluated genes, including GLI1, GLI2, PTCH1, and PTCH2, showed significant reductions. Additional in situ hybridization revealed that reduced GLI1 expression was localized to tumor tissue, with GLI1 mRNA remaining undetectable in surrounding healthy areas indicating a tumor-specific response. Unfortunately, we were not able to obtain the additional biopsies required to assess pretreatment gene expression levels in patients receiving oral vismodegib; however, the decrease in hedgehog pathway gene expression observed for topical vismodegib is within the range previously established for human BCC cell lines and found in samples from BCC patients treated with systemic vismodegib.[1,31]

10969101, 2024, 3, Downloaded from https://onlinelibrary.wiley.com/doi/10.1002/lsm.23766 by Danish Technical Knowledge, Wiley Online Library on [26/03/2024]. See the Terms and Conditions (https://onlinelibrary.wiley.com/terms-and-conditions) on Wiley Online Library for rules of use; OA articles are governed by the applicable Creative Commons License

One of the theoretical benefits of a topical administration of vismodegib would be a reduction of drug-specific adverse effects.[14,32] The topical vismodegib administration appeared to be a safe treatment modality with manageable local skin reactions that could be expected from the combined AFL and skin occlusion. Crucially, vismodegib was not detected in plasma following topical administration. Vismodegib plasma concentrations may potentially have peaked around 24–48 h and in addition, repeated applications could potentially increase vismodegib plasma concentrations. Yet, the total vismodegib dose used for AFL-assisted topical vismodegib delivery remains very low compared to the oral regimen. For this reason, the risk of adverse reactions from transdermal vismodegib uptake is expected to be limited. There may be a risk of adverse events associated with the use of AFL in the settings applied including pain sensation, the latter of which was not evaluated in the present study.

Major limitations of the study include analysis of only a single application of vismodegib and lack of assessment of clinical response. Evaluation of repeated topical vismodegib administrations, including related safety, tolerability, and clinical treatment response are needed to fully appraise AFL-assisted topical vismodegib delivery as a clinically relevant treatment modality. These evaluations were outside the scope of the present study. Another concern to address in follow-up trials would be that bleeding and oozing following AFL, aggravated by aberrant vasculature and increased interstitial fluid pressure of tumors,[33] could negatively impact vismodegib uptake. In addition, the small sample size particularly for oral vismodegib administration as well as for comparison between ulcerated and nonulcerated tumors and anatomical regions (which showed no significant differences) increase the risk of Type 1 or Type 2 errors. Due to the wide range in intratumoral vismodegib uptake following topical administration, we feel confident that tumor vismodegib concentrations after systemic and topical vismodegib would remain comparable statistically even with a larger sample size. Yet, constraints including the size of included nodular BCCs, the need for multiple invasive biopsies, and limited access to patients receiving oral vismodegib, who are relatively rare and typically fragile, have significantly limited the patient population available for this explorative study.

At this point, it remains to be explored whether topical vismodegib administration by AFL could serve as an efficacious stand-alone treatment for BCC. Alternatively, the modality could serve as adjuvant treatment before surgery, reducing tumor size, or serve in combination with other pharmacological compounds. Drugs relevant for BCC treatment including methyl aminolevulinate, 5-fluorouracil, cisplatin, and imiquimod have been investigated in combination with AFL, and the latter three also reduce expression of hedgehog pathway genes.[1,15,18,24,34–36]

# CONCLUSION

We found that AFL-assisted topical vismodegib delivery deposited vismodegib into human BCCs in vivo at intratumoral concentrations comparable to systemic oral administration. The treatment induced a substantial intratumoral biological response after a single application, characterized by reduction of GLI1, GLI2, PTCH1, and PTCH2 expression, and had a favorable safety profile with moderate local skin reactions. Together, the data suggests a potential role for AFL-assisted topical administration of vismodegib in future treatment of BCC.

## AUTHOR CONTRIBUTIONS

**Uffe H. Olesen**: Conceptualization; methodology; formal analysis; writing—original draft; visualization; funding acquisition. **Kristian Kåber Pedersen**: Formal analysis; data curation; visualization. **Katrine Togsverd-Bo**: Methodology; investigation; funding acquisition. **Edyta Biskup**: Methodology; validation; investigation. **Anni Linnet Nielsen**: Investigation. **Malene Jackerott**: Investigation; visualization. **Gael Clergeaud**: Methodology; validation; investigation. **Thomas L. Andresen**: Resources; supervision. **Merete Haedersdal**: Conceptualization; resources; writing—review and editing; supervision; funding acquisition.

## ACKNOWLEDGMENTS

The authors would like to thank Diana Høeg (Department of Dermatology, Copenhagen University Hospital—Bispebjerg) as well as Liselotte Butzkowsky Gurzulidis (LEO Pharma) for technical assistance. This study was supported by grants from Research Fund of the Capital Region of Denmark (R146-A5738; M. H.) and Research Fund of Copenhagen University Hospital—Bispebjerg (no grant number; K. T.-B.) and executed as part of Skin Cancer Innovation clinical academic group (SCIN-CAG) of Greater Copenhagen Health Science Partners (GCHSP) and the Danish Research Center for Skin Cancer (http://www.researchcenterforskincancer.org), a public-private research partnership between the Private Hospital Mølholm, Aalborg University Hospital and Copenhagen University Hospital, Bispebjerg.

## CONFLICT OF INTEREST STATEMENT

The authors declare no conflict of interest.

## ORCID

*Uffe H. Olesen* http://orcid.org/0000-0002-4578-684X
*Kristian Kåber Pedersen* http://orcid.org/0000-0002-9994-7848
*Katrine Togsverd-Bo* http://orcid.org/0000-0002-4272-4889
*Edyta Biskup* http://orcid.org/0000-0002-5510-2712
*Malene Jackerott* http://orcid.org/0000-0003-4815-2153

10969101, 2024, 3, Downloaded from https://onlinelibrary.wiley.com/doi/10.1002/lsm.23766 by Danish Technical Knowledge, Wiley Online Library on [26/03/2024]. See the Terms and Conditions (https://onlinelibrary.wiley.com/terms-and-conditions) on Wiley Online Library for rules of use; OA articles are governed by the applicable Creative Commons License

*Gael Clergeaud* http://orcid.org/0000-0003-4358-5574
*Thomas L. Andresen* http://orcid.org/0000-0002-1048-127X
*Merete Haedersdal* http://orcid.org/0000-0003-1250-2035

## REFERENCES

1. Olesen UH, Bojesen S, Gehl J, Haedersdal M. Anticancer drugs and the regulation of hedgehog genes GLI1 and PTCH1, a comparative study in nonmelanoma skin cancer cell lines. Anti-Cancer Drugs. 2017;28(10):1106–17. https://doi.org/10.1097/CAD.0000000000000551
2. Rudin CM. Vismodegib. Clin Cancer Res. 2012;18(12):3218–22. https://doi.org/10.1158/1078-0432.CCR-12-0568
3. Epstein EH. Basal cell carcinomas: attack of the hedgehog. Nat Rev Cancer. 2008;8(10):743–54. https://doi.org/10.1038/nrc2503
4. Graham RA, Lum BL, Cheeti S, Jin JY, Jorga K, Von Hoff DD, et al. Pharmacokinetics of hedgehog pathway inhibitor vismodegib (GDC-0449) in patients with locally advanced or metastatic solid tumors: the role of alpha-1-acid glycoprotein binding. Clin Cancer Res. 2011;17(8):2512–20. https://doi.org/10.1158/1078-0432.CCR-10-2736
5. Migden MR, Guminski A, Gutzmer R, Dirix L, Lewis KD, Combemale P, et al. Treatment with two different doses of sonidegib in patients with locally advanced or metastatic basal cell carcinoma (BOLT): a multicentre, randomised, double-blind phase 2 trial. Lancet Oncol. 2015;16(6):716–28. https://doi.org/10.1016/S1470-2045(15)70100-2
6. Sekulic A, Migden MR, Oro AE, Dirix L, Lewis KD, Hainsworth JD, et al. Efficacy and safety of vismodegib in advanced basal-cell carcinoma. N Engl J Med. 2012;366(23):2171–9. https://doi.org/10.1056/NEJMoa1113713
7. Dummer R, Ascierto PA, Basset-Seguin N, Dréno B, Garbe C, Gutzmer R, et al. Sonidegib and vismodegib in the treatment of patients with locally advanced basal cell carcinoma: a joint expert opinion. J Eur Acad Dermatol Venereol. 2020;34(9):1944–56. https://doi.org/10.1111/jdv.16230
8. Sekulic A, Migden MR, Basset-Seguin N, Garbe C, Gesierich A, Lao CD, et al. Long-term safety and efficacy of vismodegib in patients with advanced basal cell carcinoma: final update of the pivotal ERIVANCE BCC study. BMC Cancer. 2017;17(1):332. https://doi.org/10.1186/s12885-017-3286-5
9. Skvara H, Kalthoff F, Meingassner JG, Wolff-Winiski B, Aschauer H, Kelleher JF, et al. Topical treatment of basal cell carcinomas in nevoid basal cell carcinoma syndrome with a smoothened inhibitor. J Invest Dermatol. 2011;131(8):1735–44. https://doi.org/10.1038/jid.2011.48
10. Epstein EH, Lear J, Saldanha G, Tang JY, Harwood C. Hedgehog pathway inhibition by topical patidegib to reduce BCC burden in patients with basal cell nevus (Gorlin) syndrome. J Clin Oncol. 2018;36(15_suppl):e21626. https://doi.org/10.1200/JCO.2018.36.15_suppl.e21626
11. Lauressergues E, Heusler P, Lestienne F, Troulier D, Rauly-Lestienne I, Tourette A, et al. Pharmacological evaluation of a series of smoothened antagonists in signaling pathways and after topical application in a depilated mouse model. Pharmacol Res Perspect. 2016;4(2):e00214. https://doi.org/10.1002/prp2.214
12. Cosio T, Di Prete M, Di Raimondo C, Garofalo V, Lozzi F, Lanna C, et al. Patidegib in dermatology: a current review. Int J Mol Sci. 2021;22(19):10725. https://doi.org/10.3390/ijms221910725
13. Zhu H, Lewis DJ. Topical hedgehog inhibitors for basal cell carcinoma: how far away are we. Expert Opin Pharmacother. 2022;23(6):739–40. https://doi.org/10.1080/14656566.2022.2050215
14. Pedersen KK, Høyer-Hansen MH, Litman T, Hædersdal M, Olesen UH. Topical delivery of hedgehog inhibitors: current status and perspectives. Int J Mol Sci. 2022;23(22):14191. https://doi.org/10.3390/ijms232214191
15. Erlendsson AM, Olesen UH, Haedersdal M, Rossi AM. Ablative fractional laser-assisted treatments for keratinocyte carcinomas and its precursors-clinical review and future perspectives. Adv Drug Deliv Rev. 2020;153:185–94. https://doi.org/10.1016/j.addr.2020.01.001
16. Hædersdal M, Sakamoto FH, Farinelli WA, Doukas AG, Tam J, Anderson RR. Fractional CO(2) laser-assisted drug delivery. Lasers Surg Med. 2010;42(2):113–22. https://doi.org/10.1002/lsm.20860
17. Zhao Y, Voyer J, Li Y, Kang X, Chen X. Laser microporation facilitates topical drug delivery: a comprehensive review about preclinical development and clinical application. Expert Opin Drug Deliv. 2023;20(1):31–54. https://doi.org/10.1080/17425247.2023.2152002
18. Wenande E, Olesen UH, Boesen MR, Persson DP, Lerche CM, Stürup S, et al. Laser-assisted delivery enhances topical uptake of the anticancer agent cisplatin. Drug Deliv. 2018;25(1):1877–85. https://doi.org/10.1080/10717544.2018.1534896
19. Hendel K, Hansen ACN, Bik L, Bagger C, van Doorn MBA, Janfelt C, et al. Bleomycin administered by laser-assisted drug delivery or intradermal needle-injection results in distinct biodistribution patterns in skin: in vivo investigations with mass spectrometry imaging. Drug Deliv. 2021;28(1):1141–9. https://doi.org/10.1080/10717544.2021.1933649
20. Christensen RL, Hendel KK, Persson DP, Husted S, Olesen UH, Haedersdal M. Topical delivery of PD-1 inhibitors with laser-assisted passive diffusion and active intradermal injection: investigation of cutaneous pharmacokinetics and biodistribution patterns. Lasers Surg Med. 2022;54(1):170–81. https://doi.org/10.1002/lsm.23504
21. Christensen RL, Ortner VK, Haedersdal M, Olesen UH. Optical imaging visualizes a homogeneous and horizontal band-like biodistribution of large- and small-size hydrophilic compounds delivered by ablative fractional laser. Pharmaceutics. 2022;14(8):1537. https://doi.org/10.3390/pharmaceutics14081537
22. Christensen RL, Omland SH, Persson DP, Husted S, Hædersdal M, Olesen UH. Topical delivery of nivolumab, a therapeutic antibody, by fractional laser and pneumatic injection. Lasers Surg Med. 2021;53(1):154–61. https://doi.org/10.1002/lsm.23322
23. Cao Y, Kakar P, Hossen MN, Wu MX, Chen X. Sustained epidermal powder drug delivery via skin microchannels. J Control Release. 2017;249:94–102. https://doi.org/10.1016/j.jconrel.2017.01.030
24. Wenande E, Hendel K, Mogensen M, Bagger C, Mårtensson NL, Persson DP, et al. Efficacy and safety of laser-assisted combination chemotherapy: an explorative imaging-guided treatment with 5-fluorouracil and cisplatin for basal cell carcinoma. Lasers Surg Med. 2021;53(1):119–28. https://doi.org/10.1002/lsm.23323
25. Olesen UH, Clergeaud G, Hendel KK, Yeung K, Lerche CM, Andresen TL, et al. Enhanced and sustained cutaneous delivery of vismodegib by ablative fractional laser and microemulsion formulation. J Invest Dermatol. 2020;140(10):2051–9. https://doi.org/10.1016/j.jid.2020.01.032
26. Olesen UH, Clergeaud G, Lerche CM, Andresen TL, Haedersdal M. Topical delivery of vismodegib using ablative fractional laser and micro-emulsion formulation in vitro. Lasers Surg Med. 2019;51(1):79–87. https://doi.org/10.1002/lsm.23013
27. Olesen UH, Mogensen M, Haedersdal M. Vehicle type affects filling of fractional laser-ablated channels imaged by optical coherence tomography. Lasers Med Sci. 2017;32(3):679–84. https://doi.org/10.1007/s10103-017-2168-z
28. Chuang GS, Manstein D, Tannous Z, Avram MM. Ulceration of mature surgical scars following nonablative fractional photothermolysis associated with intralesional lidocaine injections. Dermatol Surg. 2012;38(11):1879–81. https://doi.org/10.1111/j.1524-4725.2012.02576.x
29. Wenande E, Gundavarapu SC, Tam J, Bhayana B, Thomas CN, Farinelli WA, et al. Local vasoregulative interventions impact

10969101, 2024, 3, Downloaded from https://onlinelibrary.wiley.com/doi/10.1002/lsm.23766 by Danish Technical Knowledge, Wiley Online Library on [26/03/2024]. See the Terms and Conditions (https://onlinelibrary.wiley.com/terms-and-conditions) on Wiley Online Library for rules of use; OA articles are governed by the applicable Creative Commons License

drug concentrations in the skin after topical laser-assisted delivery. Lasers Surg Med. 2022;54(10):1288–97. https://doi.org/10.1002/lsm.23558

30. Hendel KK, Bagger C, Olesen UH, Janfelt C, Hansen SH, Haedersdal M, et al. Fractional laser-assisted topical delivery of bleomycin quantified by LC-MS and visualized by MALDI mass spectrometry imaging. Drug Deliv. 2019;26(1):244–51. https://doi.org/10.1080/10717544.2019.1574937
31. LoRusso PM, Rudin CM, Reddy JC, Tibes R, Weiss GJ, Borad MJ, et al. Phase I trial of hedgehog pathway inhibitor vismodegib (GDC-0449) in patients with refractory, locally advanced or metastatic solid tumors. Clin Cancer Res. 2011;17(8):2502–11. https://doi.org/10.1158/1078-0432.CCR-10-2745
32. Halder J, Mishra A, Kar B, Ghosh G, Rath G. Recent advances in chemical composition and transdermal delivery systems for topical bio-actives in skin cancer. Curr Top Med Chem. 2023;23(1):31–43. https://doi.org/10.2174/1568026622666220902104906
33. Meaney C, Stapleton S, Kohandel M. Predicting intratumoral fluid pressure and liposome accumulation using physics informed deep learning. Sci Rep. 2023;13(1):20548. https://doi.org/10.1038/s41598-023-47988-8
34. Fontenete S, Lerche CM, Paasch U, Perez-Moreno M, Olesen UH, Haedersdal M. Tumor clearance and immune cell recruitment in UV-induced murine squamous cell carcinoma exposed to ablative fractional laser and imiquimod treatment. Lasers Surg Med. 2021;53(9):1227–37. https://doi.org/10.1002/lsm.23406
35. Gruber W, Frischauf AM, Aberger F. An old friend with new skills: imiquimod as novel inhibitor of hedgehog signaling in basal cell carcinoma. Oncoscience. 2014;1(9):567–73. https://doi.org/10.18632/oncoscience.80
36. Wenande E, Olesen UH, Nielsen MMB, Janfelt C, Hansen SH, Anderson RR, et al. Fractional laser-assisted topical delivery leads to enhanced, accelerated and deeper cutaneous 5-fluorouracil uptake. Expert Opin Drug Deliv. 2017;14(3):307–17. https://doi.org/10.1080/17425247.2017.1260119

## SUPPORTING INFORMATION

Additional supporting information can be found online in the Supporting Information section at the end of this article.

**How to cite this article:** Olesen UH, Pedersen KK, Togsverd-Bo K, Biskup E, Nielsen AL, Jackerott M, et al. Laser-assisted topical delivery of vismodegib reduces hedgehog gene expression in human basal cell carcinomas in vivo. Lasers Surg Med. 2024;56:239–48. https://doi.org/10.1002/lsm.23766

10969101, 2024, 3, Downloaded from https://onlinelibrary.wiley.com/doi/10.1002/lsm.23766 by Danish Technical Knowledge, Wiley Online Library on [26/03/2024]. See the Terms and Conditions (https://onlinelibrary.wiley.com/terms-and-conditions) on Wiley Online Library for rules of use; OA articles are governed by the applicable Creative Commons License